



INDIAN JOURNAL OF PRACTICAL PEDIATRICS



- **IJPP is a quarterly subscription journal of the Indian Academy of Pediatrics committed to presenting practical pediatric issues and management updates in a simple and clear manner**
- **Indexed in Excerpta Medica from January 2003**
- **Annual subscription:Rs. 300/- 10 years subscription:Rs.3000/-**

Vol.7 No.2

APR-JUN 2005

Dr. A. Balachandran
Editor-in-Chief

Dr. K.Nedunchelian
Executive Editor

CONTENTS

| | |
|---|------------|
| FROM THE EDITOR'S DESK | 79 |
| GUEST EDITOR'S NOTE | 82 |
| TOPIC OF INTEREST - DERMATOLOGY | |
| Clinical features of the collagen vascular disorders in children | 83 |
| - Ian McColl | |
| Urticaria in infants and children | 88 |
| - Sandipan Dhar | |
| Adverse cutaneous drug reactions in children | 94 |
| - Devinder Mohan Thappa, Shivaswamy KN | |
| Childhood bacterial skin infections | 101 |
| - Sangeeta Amladi | |
| Pediculosis and scabies in children | 106 |
| - Shahbaz A Janjua | |

Journal Office: Indian Journal of Practical Pediatrics, IAP-TNSC Flat, 'F' Block, Ground Floor, Halls Towers, 56, Halls Road, Egmore, Chennai - 600 008. INDIA. Tel.No. : 044-28190032 E.mail : ijpp_iap@rediffmail.com

Address for ordinary letters: The Editor-in-Chief, Indian Journal of Practical Pediatrics, Post Bag No.524, Chennai 600 008.

Address for registered/insured/speed post/courier letters/parcels and communication by various authors: Dr. A. Balachandran, Editor-in-chief, Indian Journal of Practical Pediatrics, "F" Block, No. 177, Plot No. 235, 4th Street, Anna Nagar East, Chennai - 600 102. Tamil Nadu, INDIA.

Emergencies in pediatric dermatology 112

- Jayakar Thomas

MANAGEMENT UPDATE**Bacterial meningitis in the post neonatal period 133**

- Potharaju Nagabhushana Rao, Potharaju Anil Kumar

RADIOLOGIST TALKS TO YOU**Neonatal jaundice 157**

- Vijayalakshmi G, Natarajan B, Ramalingam A

CASE STUDY**Congenital esophageal stenosis 160**- Malathi Sathiyasekaran, Lalitha Janakiraman, Shivbalan So,
Deenadayalan M**Fibrodysplasia ossificans progressiva - A case report 162**

- Arulprakash, Rakesh Kain, Maya Chansoria

BOOK REVIEW 132, 165**NEWS AND NOTES 82, 87, 100, 105, 132, 156, 159, 164, 166****FOR YOUR KIND ATTENTION**

* The views expressed by the authors do not necessarily reflect those of the sponsor or publisher. Although every care has been taken to ensure technical accuracy, no responsibility is accepted for errors or omissions.

* The claims of the manufacturers and efficacy of the products advertised in the journal are the responsibility of the advertiser. The journal does not own any responsibility for the guarantee of the products advertised.

* Part or whole of the material published in this issue may be reproduced with the note "Acknowledgement" to "Indian Journal of Practical Pediatrics" without prior permission.

- Editorial Board

Published and owned by Dr. A. Balachandran, from Halls Towers, 56, Halls Road, Egmore, Chennai - 600 008 and printed by Mr. D. Ramanathan, at Alamu Printing Works, 9, Iyyah Mudali Street, Royapettah, Chennai - 600 014. Editor : Dr. A. Balachandran.

FROM THE EDITOR'S DESK

Greetings from the Journal Committee of IJPP! In this issue we are focusing on Pediatric Dermatology. We profusely thank Dr.Jayakar Thomas, Guest Editor for this issue who has carefully chosen the topics and authors for this issue. We also thank Dr.Vijayabhaskar, Dr.V.Anandan and Dr.R.Madhu the office bearers of IAP Dermatology Group for coordinating with the Guest Editor and Journal Committee for meticulously going through the manuscript in detail. We all know that Pediatric Dermatology is very interesting subject and it varies distinctly from adult skin disorders. Thus, these topics will definitely enrich the knowledge of practicing pediatrician on practical dermatological problems. Dr.Jayakar Thomas in his note on Guest Editor mentioned that the pediatric dermatology is now advancing at a greater speed and more and more information will come in the near future.

‘Collagen vascular disorders in children’ written by Dr.Ian McColl from Australia is a good review on some of the conditions like lupus erythematosus, dermatomyositis, scleroderma, etc, which will be very useful for the postgraduates and the practicing pediatrician. ‘Urticaria in children’ is the common skin condition encountered in the clinical practice. Dr.Sandipan Dhar has given a clear account on the causes of urticaria, the management and review on current literature.

‘Drug reaction in children’ is very alarming for the parents as well to the practitioners. DM Thappa, et al has written in detail the epidemiology, pathogenesis and the clinical features of various drug eruptions. We hope this article will bring more light on this controversial subject. Dr.Sangeeta Amladi has contributed the article on ‘Childhood bacterial skin infections’. She has mentioned that bacterial skin infections are the most common in

pediatric age group and may serve as a marker for underlying immune deficiency state.

Dr.Shabhaz A Janjua from Pakistan has written in detail about ‘Pediculosis and scabies in children’, which are the most common causes for itchy skin disorders in tropics. The author has given a vivid picture on the parasites, clinical features and the management of these itchy disorders. With his vast experience and clinical knowledge on dermatology Dr.Jayakar Thomas has dealt in detail about the ‘Emergencies in pediatric dermatology’. He has stressed the need for intensive care for these conditions and we have to start thinking of intensive skin care unit in the near future. The differentiating features between SSSS, SJS and TEN will serve as a ready reckoner for the practitioners.

Under the management update the article on ‘Bacterial meningitis in the post neonatal period’ written by Nagabhushana Rao P, et al will be an academic feast to the young postgraduates and pediatricians who are dealing with very sick children in the hospital settings. He has written extensively on the current trends in the management of this dreadful clinical condition. Under the popular heading on ‘Radiologist talks to you’, Vijayalakshmi G, et al has written on ‘Evaluation of neonatal jaundice’. They have mentioned the role of imaging in an infant with neonatal jaundice to decide the surgical intervention.

The Journal Committee profusely thanks our Guest Editor and the Pediatric Dermatology Group for their effort in bringing out this special issue. We also thank all the authors for contributing interesting articles in this issue.

Dr. A.Balachandran
Editor-in-Chief

INSTRUCTIONS TO AUTHORS**General**

Print the manuscript on one side of standard size A4, white bond paper, with margins of at least 2.5 cm (1") in double space typescript on each side. Use American English using Times New Roman font 12 size. Submit four complete sets of the manuscript.

They are considered for publication on the understanding that they are contributed to this journal solely.

All pages are numbered at the top of the right corner, beginning with the title page.

All manuscripts should be sent to: The Editor-in-Chief, Indian Journal of Practical Pediatrics

Manuscript**1st Page –**

Title

Name of the author and affiliation

Institution

Address for correspondence (Email, Phone, Fax if any)

Word count

No. of figures (colour / black and white)

No. of references

Authors contribution

2nd Page –

Abstract (unstructured, not exceeding 100 words) with key words (not exceeding 4)

3rd Page -

Acknowledgement

Points to remember (not more than 5 points)

Text

References

Tables

Legends

Figures – should be good quality, 4 copies black & white / colour,*

(4 x 6 inches – Maxi size) Glossy print

* Colour images will be charged separately

Text

Only generic names should be used

Measurements must be in metric units with System International (SI) Equivalents given in parentheses.

References

Recent and relevant references only

Strictly adhere to Vancouver style

Should be identified in the text by Arabic numerals in parentheses.

Type double-space on separate sheets and number consecutively as they appear in the text.

Defective references will entail rejection of article

Tables

Numbered with Roman numerals and typed on separate sheets.

Title should be centered above the table and explanatory notes below the table.

Figures and legends

Unmounted and with figure number, first author's name and top location indicated on the back of each figure.

Legends typed double-space on separate sheet. No title on figure.

All manuscripts, which are rejected will not be returned to author. Those submitting articles should therefore ensure that they retain at least one copy and the illustration, if any.

Article Categories

Review article

Article should be informative covering the recent and practical aspects in that field. Main articles can be in 1500 – 2000 words with 12 – 15 recent references and abstract not exceeding 100 words.

Case report (covering practical importance)

250 – 600 words, 8 – 10 recent references

Clinical spotters section

150 – 200 words write up

With 1 or 2 images of clinically recognizable condition

(of which one could be in the form of clinical photograph / specimen photograph / investigation)

Letters to the Editor

200 – 250 words pertaining to the articles published in the journal or practical viewpoints with scientific backing and appropriate references in Vancouver style.

Selection procedures

All articles including invited articles will be peer reviewed by two masked reviewers. The decision of the Editorial Board based on the reviewers' comments is final.

Check List

Covering letter by corresponding author

Declaration (as enclosed) signed by all authors **

Manuscript (4 copies)

Accompanied by a copy in CD / or submit as an email attachment in addition to hard copy.

Failing to comply with the requirement at the time of submission would lead to the rejection of the article.

Author's contribution / Authorship Criteria

All persons designated as authors should qualify for the authorship. Authorship credit should be based on substantial contributions to i) concept and design, or collection of data, or analysis and interpretation of data; ii) drafting the article or revising it critically for important intellectual content; and iii) final approval of the version to be published. All conditions 1, 2 and 3 must be met. Participation solely in the collection of data does not justify authorship and can be mentioned in the acknowledgement if wanted.

Declaration by authors **

I/We certify that the manuscript titled '.....' represents valid work and that neither this manuscript nor one with substantially similar content under my/our authorship has been published or is being considered for publication elsewhere. The author(s) undersigned hereby transfer(s), assign(s), or otherwise convey(s) all copyright ownership, including any and all rights incidental thereto, exclusively to the Indian Journal of Practical Pediatrics, in the event that such work is published in Indian Journal of Practical Pediatrics. I / we assume full responsibility for any infringement of copyright or plagiarism.

Authors' name(s) in order of appearance in the manuscript

Signatures (date)

GUEST EDITOR'S NOTE

Pediatric dermatology is a fascinating speciality. Needless to say that the pediatric skin differs in more than one way from its adult counterpart – anatomically, physiologically, pathologically and in response to treatment. More of it is described in the pages to follow.

As one practicing pediatric dermatology, it is indeed my pleasure to be the Guest Editor of this issue of the Indian Journal of Practical Pediatrics (IJPP) that deals with “Pediatric skin disorders”. At the very outset, I must thank the Editor-in-Chief, Dr. A. Balachandran for giving me this opportunity.

Given the speed at which pediatric dermatology is now advancing and the interest shown by pediatricians and dermatologists alike, I am forced to humbly accept the fact that the utility of this issue is likely to get outdated rapidly. However my colleagues who have contributed to this issue have made every attempt to highlight the fundamentals, which will never change. Readers may add on subsequently. The topics are of importance in day-to-day practice and have been dealt with the utmost care and

concern to the reader and to the child patient. Bacterial dermatoses, Scabies and Pediculoses, Urticaria, Collagen Vascular Disorders and Adverse Cutaneous Drug Reactions are seen every day in a busy out-patient department and these topics have been written by authorities in the respective subjects. For this I acknowledge my colleagues Drs, Sangeeta Amladi, Shahbaz Janjua, Sandipan Dhar, Ian McColl and Devinder Thappa. The article on Emergencies in Pediatric Dermatology is added for academic reasons and for the inhouse physicians.

My special thanks to our overseas contributors Dr. Shahbaz Janjua from Pakistan and Dr. Ian McColl from Australia for their instant acceptance to send in their articles.

Finally, I have to immensely thank my wife Dr. Nirmala Thomas for the cooperation and help rendered by her in compiling this work.

Dr. Jayakar Thomas

Senior Consultant Dermatologist,
Apollo Hospitals and

Kanchi Kamakoti CHILDS Trust Hospital,
Chennai, India

NEWS AND NOTES**RESPICON 2005**

Organized by

IAP Respiratory Chapter & IAP Environment & Child Health Group

Hosted by

IAP Respiratory Chapter, Karnataka State Branch

Co-Sponsors: IAP-BPS, Bangalore Branch.

Venue: Jnana Jyothi Convention Hall, Central College Campus, Bangalore, Karnataka.

Date: 10th and 11th September 2005

Address for correspondence: Dr.S.Nagabhushna, Organizing Secretary, RESPICON 2005, Ashwini Health Centre, I main II cross, Sundar Nagar, Gokula Post, Bangalore – 560 054.

Email: nagabhushana_s@rediffmail.com

DERMATOLOGY

CLINICAL FEATURES OF COLLAGEN VASCULAR DISORDERS IN CHILDREN

* **Ian McColl**

Abstract: Collagen vascular diseases encompass a group of diseases that are seen both in adults and in children. In this review, emphasis is on certain findings that differentiate the conditions between children and adults. The diseases considered include lupus erythematosus, dermatomyositis, scleroderma, mixed connective tissue disease and Sjogren's syndrome

Key words: *Scleroderma, Lupus Erythematosus, Dermatomyositis, Mixed Connective Tissue Disease*

Lupus erythematosus

Lupus erythematosus can present very early in childhood as neonatal lupus. This condition is seen in the children of mothers who are Ro antibody positive¹. The children present with annular lesions in sun exposed areas and with increased photosensitivity. Cardiac involvement occurs in 75% of cases with congenital heart block seen in 15% to 30% of affected infants². This heart block is irreversible. However the cutaneous changes are reversible. These infants initially show increased sun sensitivity developing into diffuse erythema in sun exposed areas particularly around the periocular skin. However they may also develop the lesions of

discoid lupus and the annular lesions more typical of subacute lupus³. Most cases are female with an 8:1 ratio to males. This is the same ratio that is seen in systemic lupus. More chronic lesions will show the features of discoid lupus with scaling, atrophy and hypo or hyperpigmentation. Infants with neonatal lupus are typically born to mothers with systemic lupus, rheumatoid arthritis or some other type of mixed connective tissue disease.

Infants with neonatal lupus have also shown thrombocytopenia⁴, aplastic anaemia, mild liver involvement and rarely CNS vasculopathy. Skin lesions of neonatal cutaneous lupus may be present at birth so sunlight is not necessarily a prerequisite for the development of the rash³. However most cutaneous lesions occur within a few days of birth and can occur on any part of the body, including the scalp, but they are seen most frequently around the eyes. The lesions are often annular with slightly scaly plaques similar to those seen in subacute lupus. Telangiectasia may persist at sites of previous lesions and this telangiectasia can last for some years³. The skin lesions themselves usually disappear by about 7 months of age but may rarely persist for as long as 15 months. This is usually related to the disappearance of the mother's Ro antibody from the child's bloodstream. The differential diagnosis of these lesions include atopic eczema, seborrhoeic dermatitis, psoriasis, tinea faciei and photosensitive genodermatoses such as Bloom's syndrome, Rothmund-Thomson and Cockayne syndrome.

Lupus erythematosus in childhood usually presents as systemic lupus rather than as localised benign cutaneous discoid lupus. The peak

* Dermatologist
John Flynn Medical Centre,
Tugun, Gold Coast,
Australia.

incidence of the disease is around the age of 12 years and the condition is usually more acute and severe than that found in adults. Morphologically the classic discoid lupus lesions are the commonest skin manifestation of systemic lupus erythematosus in childhood. The classic features of discoid lupus lesions are scaling with follicular plugging, telangiectasia and hypopigmentation. The cutaneous lesions may be the presenting feature of systemic lupus in childhood in about 25% of cases. The butterfly rash consists of erythema and scaling particularly over the nose and cheek areas. Crusting and scaling of the lower lip is an additional feature because it is the most sun exposed site. Children with systemic lupus also develop a diffuse sunburn like rash and may also develop plaques. These may show the typical features of discoid lupus being annular with thick carpet tack like scale, atrophy and both hypo and hyperpigmentation. The hyperpigmentation is particularly common on the outside of a lesion representing a lesser degree of basal layer damage than the hypopigmented area. Mucous membrane lesions comprising of erosions, gingivitis and mucosal haemorrhage may be seen.

Scarring alopecia is also a feature of lupus. Increased fragility of the hair results in hair broken off at different levels, with the patient developing a receding hairline.

Livedo reticularis, reticulated bluish red discolouration of the skin with a net like pattern, is more particularly seen in other connective tissue diseases such as scleroderma, but it is also a feature of systemic lupus. It is made worse by exposure to cold. Raynaud's phenomenon characterised by a stark white digit that subsequently goes blue on exposure to cold is a feature of lupus, but perhaps a more common feature in scleroderma. It may precede the onset of the condition by months to years.

Urticarial vasculitis is another cutaneous manifestation of systemic lupus in children.

Unlike normal urticaria the hive like lesions last longer than 24 hours and often have haemorrhage left after the lesion has cleared, particularly at the peripheries of the hives. Urticarial vasculitis may be associated with hypo complementemia.

Telangiectasia of the nail folds is common to scleroderma, dermatomyositis and lupus erythematosus, but a papular telangiectasia of the palms and fingers is more common in lupus. Occasionally the vasculitis of lupus can give rise to small peripheral cutaneous infarcts, but this phenomenon is more commonly seen in scleroderma than in lupus.

Chilblains or perniosis are tender purplish nodules at the peripheries particularly of the fingers and toes. This may also be a presenting feature of both systemic and discoid lupus.

Lupus profundus characterised by facial depressions due to loss of subcutaneous fat with associated hypo and hyperpigmentation may be seen with associated discoid lupus but also in systemic lupus. Around 50% of patients with lupus profundus will eventually develop systemic lupus. These lesions are usually seen on the forehead, cheeks and buttocks.

Dermatomyositis

The clinical features of dermatomyositis are much the same in children as in adults except for calcinosis which is much more common in children. Unlike dermatomyositis in adults, children do not show an association with underlying malignancy. In a child, look for the heliotrope periocular rash involving the upper and lower eyelids, photosensitivity and other diffuse erythema particularly over the extensor surfaces of the knees and elbows. On the hands this erythema is prominent over the interphalangeal joints in contradistinction to lupus erythematosus where it is the area of skin between the joints

that is more usually inflamed. Generally in dermatomyositis in children, the skin features will precede the joint weakness by three to six months. The condition is more common in females than males, but the ratio is only 2:1. In children the commonest age for this condition is between five and 12 years. The other clinical features that are different in children compared to adults are that they rarely have Raynaud's phenomenon and have more muscle weakness and involvement. Gottron's papules are seen on the dorsal interphalangeal joints and extensor surfaces of the elbows and knees. They present as erythematous and violaceous flat top papules but are seen in both adults and children. Facial oedema can also be seen. The cuticles at the base of the nails show fairly typical changes in dermatomyositis. The cuticles themselves are thickened, rough and scaly as if they have been traumatised. Under the dermatoscope the capillary loops show linear telangiectasia and loop drop out, but this does not allow you to differentiate between dermatomyositis, lupus and scleroderma. As in lupus and scleroderma there may be infarcts of the tips of the fingers due to angiitis. Facial hypertrichosis and hyperpigmentation is more common in children with dermatomyositis than in adults. This is independent of the use of steroid therapy. Cutaneous erythema and dermatomyositis fluctuate from day to day. It is certainly exacerbated by sun exposure and is more common over the elbows, knees and shoulder tips as well as the face, but in some cases the myositis may be much more marked than the dermatitis. Late in the chronic stages of juvenile dermatomyositis, poikiloderma can be seen. This is characterised by hypo and hyperpigmentation with telangiectasia and white atrophy. As many as 40% of children can get oral lesions, with involvement of the palate and buccal mucosa and the gum margin with lichen planus like whitish patches on the tongue and buccal mucosa⁵.

The muscle weakness in children is the same as in adults involving particularly the large muscles of the thighs and arms known as the limb girdle muscles. The rash in dermatomyositis usually gives a history of being worse after sun exposure and may precede the development of muscle weakness by some months, sometimes years. However the dermatitis over the knuckles and the eyelid rash are usually the first manifestations of the condition. The presenting clinical characteristics of children with dermatomyositis were described by Pachman indicating that 100% of the children had a rash and proximal muscle weakness with reducing frequencies for other clinical features, but with 23% showing calcinosis⁶. A periocular facial rash is a common feature in dermatomyositis but facial oedema is also seen. Scarring and non-scarring alopecia can also be seen. Calcinosis that develops in dermatomyositis in children generally appears late in the course of the illness. Cutaneous calcinosis is a feature of childhood dermatomyositis that is not seen to the same extent in adult onset dermatomyositis, being seen in about 70% of cases of the juvenile variant but in only about 5% of adult cases. The calcium deposits are usually seen on the buttocks, shoulders and elbows and may be extruded from the skin causing chronic ulceration. Paradoxically children showing this complication have a more favourable prognosis.

The worse the initial inflammation of the skin in dermatomyositis, the more likely the child is to develop severe calcinosis, but nowadays with good treatment this inflammation is shut off early and calcinosis is less likely to be seen. The calcinosis in dermatomyositis can take a variety of patterns including superficial plaques or nodules in the extremities, calcinosis circumscripta which is deeper and usually seen in the proximal muscles, calcinosis universalis and mixtures of these forms⁷.

Scleroderma

Systemic sclerosis and systemic scleroderma not only involves the skin but also is a generalised disorder of connective tissue involving the lungs, heart, gastrointestinal tract, joints and kidneys. Again it is more frequent in females than males. The typical case in children begins with Raynaud's phenomenon and sclerodactyly. This also is in contradistinction, the diffuse form that begins with thickening over the trunk but subsequently spreads to the extremities. Raynaud's phenomenon is usually absent in this variant and the sex distribution is equal. Raynaud's phenomenon is more commonly seen in systemic sclerosis than it is in the other connective tissue diseases of childhood. A digit usually goes pale or chalk white on exposure to cold which wears off in half an hour developing cyanosis and hyperemia with associated pain and burning. It primarily affects the fingers and toes, but it can affect other acral areas.

In children as in adults the face is characteristically involved with pinching of the nose, perioral fissuring and a tight smooth forehead. Sclerodactyly affects the fingers causing swelling and tightness of the skin with loss of the normal skin markings. As the sclerosis continues the fingers will often show flexion deformity and ulceration may occur in the fingertips. Occasionally calcium is laid down in these areas as well. This may subsequently ulcerate.

Telangiectasia usually occurs on the face and is described as being mat like. These lesions are larger and more diffuse than those of the linear telangiectasia seen in other collagen diseases. They are often macular or square shaped and hence are known as telangiectatic mats. The CREST syndrome is seen in both children and adults and describes Calcinosis, Raynaud's phenomenon, Esophageal dysfunction, Sclerodactyly and Telangiectasia. The

oesophageal involvement gives rise to dysphagia and reflux.

Sjogren's syndrome, which is a symptom complex of dry mouth and dry eyes, is an inflammatory process affecting salivary and lacrimal glands. It can be a primary process on its own but it is often seen in children in association with other autoimmune diseases which have been described in this article. Here again females outnumber males. The mean age of presentation in the paediatric population is 11 years⁸.

Sjogren's syndrome is really quite rare in childhood. The cutaneous features are much the same as in adults and are due to inflammation of the exocrine secretory glands. Patients typically present with a chronically dry mouth and eyes and also parotid gland enlargement. Again as with most of the connective tissue diseases, the majority of patients are females. The lack of oral secretions gives rise to cracked, fissured or ulcerated lips and angular cheilitis. The teeth often are in very poor condition and decay easily. The tongue can be smooth, red and cracked. The skin itself is generally dry and scaly particularly on the peripheries. This is obviously worse in the cooler drier winter months. Purpura on the lower legs is a common cutaneous manifestation. Raynaud's phenomenon and telangiectasia of the lips and fingers is also seen.

Mixed connective tissue disease

Mixed connective tissue disease is again a rare condition in childhood. The cutaneous findings in children are an amalgam of the findings that are seen in the other collagen disorders described in this article. It can contain combinations of lupus, dermatomyositis, scleroderma and Sjogren's syndrome so that sclerodactyly may be seen with a heliotrope rash, but generally these patients present with features similar to lupus and with some

Raynaud's and associated joint problems.⁹ There are some clinical differences between adult and childhood forms of mixed connective tissue disease. Thrombocytopenia is usually only seen in childhood forms and renal and cardiac problems are much higher in children than in adults with the same condition.

Points to remember

1. *Collagen vascular diseases are not common in children.*
2. *An unusual persisting skin rash with fever and joint pains are clues to suspect this group of conditions.*
3. *Renal parameters are to be closely monitored.*

References

1. Lee LA, Frank MB, McCubbin VR, et al. The autoantibodies of neonatal lupus erythematosus. J Invest Dermatol 1994; 102:963-966.
2. Korkij W, Soltani K. Neonatal lupus erythematosus: a review. Pediatric Dermatol 1984; 1(3):189-195
3. Weston WL, Morelli JG, Lee LA. The clinical spectrum of anti-Ro-positive cutaneous neonatal lupus erythematosus. J Am Acad Dermatol 1999;40(5 Pt 1):675-681.
4. Watson RM, Kang JE, May M et al. Thrombocytopenia in the neonatal lupus syndrome Arch Dermatol 1988; 124:560.
5. Hamlin C, Shelton JE. Management of oral findings in a child with an advanced case of dermatomyositis. Pediatr Dent 1984; 6:46.
6. Pachman LM, Hayford JR, Chung A et al. Juvenile dermatomyositis at diagnosis: clinical characteristics of 79 children. J Rheum 1998; 25(6):1198.
7. Blane CE, White SJ, Braunstein EM et al. Patterns of calcification in childhood dermatomyositis. Am J Radiol 1984;142:397.
8. Chudwin DS, Daniels TE, Wara DW et al. Spectrum of Sjogren's syndrome in children. J Pediatr 1981;98:213.
9. Singsen BH, Bernstein BH, Kornreich HK et al. Mixed connective tissue disease in childhood: a clinical and serological survey. J Pediatr 1977;90:893.

NEWS AND NOTES

Lakeside Education Trust 23rd Annual CME

Subject: 'Poor Pourrie for the Practising Pediatrician' (Skin, Eye, Ear, Nose, Teeth, Hair as markers in systemic and local disease)

Date: 24th July 2005

Venue: Hotel Atria, Bangalore

Address for Correspondence: Dr.H.Paramesh, Chairman, Lakeside Education Trust, 23rd Annual CME Secretariat, Lakeside Medical Center & Hospital, 33/4, Meaneer Avenue Road, Near Ulsoor Lake, Bangalore - 560 042. Phone: 080-25303677, 25304276, 25566738, 25366723, 25512934
Fax: 25303677, Email: dr_paramesh1@rediffmail.com

MAHAPEDICON-2005, AMRAVATI

XVI, Maharashtra State Conference of IAP, Maharashtra State Branch

Date: November 11, 12 & 13th 2005

Contact:- Dr. Satish Tiwari / Dr. Satish Agrawal / Dr. Manoj Rathi, Org. Secretaries.

Secretariat:- Yashodanagar No. 2 Amravati Maharashtra 444606 Ph. (0721) 2672252, 5612680

E-mail : ati_drtiwari@sancharnet.in ati_drsva99@sancharnet.in dr_manojr@yahoo.com

DERMATOLOGY**URTICARIA IN PEDIATRIC PRACTICE**

*** Sandipan Dhar**

Abstract: *In infants and children the clinical manifestation of urticaria as well as its deeper counterpart angioedema do not differ from those that occur in adults. The causes of urticaria in children are usually not many and so is easier to eliminate and treat. This article reviews these considerations.*

Key Words: *Urticaria, angioedema, drug reactions, infections*

Urticaria (hives, nettle rash) manifests as itchy transient erythematous and oedematous eruptions over skin which last from few minutes to several hours. It disappears spontaneously leaving behind normal looking skin. Angio-oedema (Quincke's oedema) manifests as localised swelling of the skin and mucosa with stinging sensation. It lasts for 30 minutes to 24 hours.

Since papular urticaria, mastocytosis and urticarial vasculitis are not exactly urticaria they are not discussed here.

Frequency of urticaria and angio-oedema

Urticaria is quite frequent in childhood. However, they mostly appear as acute episode and chronic urticaria is not as common in children as compared to adults¹. Urticaria is fairly

uncommon below 6 months and rare in neonatal period. The incidence was found to be 8% of school children in Sweden and 3.5% in UK². It has been found in studies that cases of isolated urticaria constitutes 85% of total cases of urticaria, isolated angio-oedema in 6% of cases and cases of urticaria and angio-oedema together in 9% of cases³.

Urticaria in neonates and infants

Urticaria in neonates and infants usually follows a benign course. However cases of physical urticarias and a condition known as neonatal onset multisystem inflammatory disease (NOMID) usually follow a chronic course^{1,4}. Whenever one comes across a case of chronic urticaria in an infant below 6 months' age, one has to adequately rule out the possibility of cow's milk allergy⁵.

Neonatal onset Multisystem Inflammatory Disease (NOMID): It is a condition of unknown aetiology. It manifests as progressive growth retardation, frontal bossing, and retarded closure of fontanel. Various neurologic symptoms are headache, vomiting and seizures. Skin rash appears either at birth or by 6 months of age. It manifests as generalized evanescent persistent urticarial wheals. Treatment is symptomatic.

Main causes of childhood urticaria

Various causes have been highlighted in Table 1⁷. One has to remember that viral infections are the leading causes of acute urticaria in children. Often it is seen that a child being brought by his/her parents for having chicken pox and urticaria simultaneously. Another issue is parasitic infestations. The role of worm

* Associate Professor ,
Paediatric Dermatology Unit,
Institute of Child Health, Kolkata

infestations in chronic urticaria in adults is negligible. In children, parasitic infestations are often implicated in cases of urticaria, although, may be overestimated at times⁷. Another important cause of urticaria in paediatric age group is insect bites.

Inhalants, contact allergens and urticaria:

Various inhalants, contact allergens are often associated with development of urticaria in children mostly having personal and/or family history of 'atopy'. Various pollens from plants, ragweed and grass, various animal danders from cats, dogs, horses, often cause urticaria in predisposed children. Contact with caterpillars can cause urticaria in children. Prolonged contact with latex can cause urticaria in children^{8,9}. This

is particularly common in children who had been operated for spina bifida or other congenital malformations. Subsequently such cases of urticaria can get aggravated in children while eating chewing gum etc.

Vaccination and urticaria: The conventional belief is that urticaria can develop as a part of anaphylaxis and serum¹⁰ sickness following vaccination because of sensitization by foreign proteins from serum and egg proteins on which viruses are grown. However, now it has been established beyond doubt that "children allergic to eggs can be immunized safely with viruses grown on eggs"¹¹. There are only occasional reports of serum sickness due to horse/rabbit antiserum.

Table 1. Principal causes of urticaria in children

| | | |
|-----------------|-----------|--|
| Infections: | Viral | Hepatitis B, influenza, adenovirus and enterovirus infections, infectious mononucleosis. |
| | Bacterial | Streptococcus Gr A and Gr B. |
| | Parasitic | Giardia, Toxocara canis, trichinosis ⁶ |
| Drugs | | Penicillins and cephalosporins |
| | | NSAIDs |
| | | Histamine liberators e.g., codeine, radio contrast products. |
| Insect bites | | Sting by bee, wasp or any other poisonous insects. |
| Food items | | Cow's milk, especially below 6 months of age. |
| | | Egg, especilly uncooked egg white. |
| | | Fish and sea food |
| | | Peanuts and tree nuts. |
| | | Various exotic foods, some of which may cross react with latex. |
| Food additives | | Tartarazine |
| | | Sodium metabisulphite |
| Physical agents | | Cholinergic urticaria |
| | | Cold urticaria |
| | | Dermographism |
| | | Idiopathic |

Rare causes of childhood urticaria

These are rare but important causes of urticaria (mostly chronic) in children. Whenever, the cause of urticaria in a given child is not apparent, one has to consider these rare causes which are given in Table 2.

Differential diagnosis of urticaria and angio-oedema

Although in majority of the cases, for an experienced clinician, diagnosis of urticaria in a child is not at all a problem, in some situations it may be difficult. Some of the conditions which, though rare, may simulate urticaria/angio-oedema have been highlighted in Table 3.

Difference from urticaria in adults

Urticaria in pediatric age group significantly differs from that in adults on several accounts as follows :

- I. Etiological factors are more readily identifiable in infants and children as compared to adults.
- II. Acute urticaria is seen more frequently in children as compared to frequent occurrence of chronic urticaria in adults.
- III. Infections are a very important cause of urticaria in pediatric age group as compared to that in adults.
- IV. Various food articles e.g., cow milk, fish, egg, peanuts are commonly implicated in children as compared to food additives playing a more important role in adult urticaria.
- V. Various drugs are often implicated in causation of urticaria in adults. In children, however, drugs are not that important cause for urticaria¹².

Table 2 : Some rare causes of urticaria in children

| | |
|---|--|
| Urticaria associated with systemic diseases | <ul style="list-style-type: none"> · Juvenile rheumatoid arthritis, systemic lupus erythematosus · Kawasaki's disease · Mastocytosis · Gleich syndrome (recurrent angio-oedema and eosinophilia) · Dermatitis herpetiformis. · Hyper IgD syndrome (recurrent fever, arthralgia and abdominal pain) · Hypothyroidism · Lymphoma, leukemia |
| Urticaria associated with genetic disorders | <ul style="list-style-type: none"> · Hereditary angio-odema (both type I and II) · Genetic physical urticarias · Metabolic disorders a) Muckle-Weel's syndrome (urticaria with amyloidosis and deafness)¹³ b) Familial mediterranean fever c) Erythropoietic protoporphyria. |

VI. In cases of chronic urticaria in adults, often in search of an etiology, one lands up in either collagen vascular disease or lymphoreticular malignancy viz, lymphoma, leukemia etc. In children, however, such causes are rare¹³.

Natural history and prognosis

Natural history of urticaria in children is extremely variable. Course of most of the cases of ordinary urticaria/angio-odema is benign and resolve on its own in a short span of time. The duration of an acute attack on an average is few hours (particularly in cases of urticaria caused by food and/or insect bites). In severe cases, the duration may be several days e.g., urticaria caused by infections or cases of serum sickness. By and large two thirds of the cases of acute urticaria may become symptom free within two months^{1,6,8,14}. Contrary to the popular belief, incidence of chronic urticaria was found to be fairly common to the tune of 79.50% in children in an Indian study¹⁵. It has been found that one third of newly affected children have symptoms of chronic urticaria even 1 year after an acute attack. Recurrent attacks mostly occur during acute episodes of infections and their drug therapy. On an average mean duration of chronic urticaria is 16 months in children. Higher incidence of resolution has been found in girls

and children below 8 years of age are supposed to suffer less as compared to their older counterparts. Overall prognosis is, however, favourable in children as compared to adults^{16,17}.

Management of urticaria and angio-oedema in children

In majority of the cases of urticaria in children, no investigation is required. Examination of peripheral blood and estimation of absolute eosinophil count may be done. Estimation of total and specific serum IgE may be carried out in chronic cases of urticaria.

Oral antihistamines form the mainstay of treatment of urticaria. Classical H₁ blockers have sedative and anticholinergic effects. However, sedation is usually not a problem below 3-4 years of age. There has been few pharmacokinetic studies of antihistamines in children. Most of the prescribing patterns are empirically based upon clinical experience¹⁸. By and large the onset of action of most antihistamines is 30-60 minutes after ingestion. However, full action is not reached for 2-3 hours. Various antihistamines used in children for urticaria are highlighted in Table 4.

There is little reason to choose one antihistamine over another except for avoidance

Table 3. Differential diagnosis of urticaria and angio-oedema

| | |
|--------------|---|
| Urticaria | <ul style="list-style-type: none"> · Erythema multiforme (in infants) · Acute hemorrhagic oedema in children (mostly below 3 years of age). · Henoch – Schonlein purpura · Insect bites · Mastocytosis · Annular erythemas of newborn |
| Angio-oedema | <ul style="list-style-type: none"> · Acute hemorrhagic oedema · Contact dermatitis · Cellulitis / erysipelas |

Table 4 : Antihistamines used in the treatment of urticaria in infants and children

| | |
|----------------------|--|
| Sedative | |
| · Promethazine | 0.5 mg/kg/dose |
| · Pheniramine | 1.5 mg/kg/day |
| · Chlorpheniramine | 0.35 mg/kg/day |
| · Clemastine | 0.125-0.25 mg bd 2-6 yrs, 0.5-1.0 mg bd 6-12 yrs, 1 mg bd > 12 yrs |
| · Hydroxyzine | 1-2 mg/kg/day |
| · Ketotifen | 1 mg/day |
| · Cyproheptadine | 0.25 mg/kg/day |
| Mild Sedative | |
| · Cetirizine | 0.25 mg/kg/day |
| Non Sedative | |
| · Fexofenadine | 30 mg bd 6-12 yrs |
| · Loratadine | 5 mg/day <30 kg (to be used only above 2 yrs of age) |

of adverse effects, including sedation in school going children¹⁸. However the usually chosen H₁ blockers are chlorpheniramine, hydroxyzine and diphenhydramine. They are to be advocated orally twice daily in syrup or tablet form.

On an average, for cases of acute urticaria 5 to 10 days' antihistamine therapy is required; for cases of chronic urticaria the duration of treatment varies between 3 to 6 months. For cases not responding to oral antihistamine, H₂ receptor blocker e.g., ranitidine may be added. For school going or older children, a combination of non sedating antihistamine during day time and sedating antihistamine at night time is preferred.

In general antihistamines are extraordinarily safe¹⁸. New born babies sometime develop paradoxical CNS excitation and convulsions to some sedative antihistamines viz., promethazine, hydroxyzine etc. This is thought to be due to anticholinergic effect of these drugs.

For cases of anaphylaxis, acute urticaria with angio-oedema, adrenaline (epinephrine) is the drug of choice. It is to be given subcutaneously at a dose of 0.05 mg/kg/day in two divided doses. Alternatively hydrocortisone, methylprednisolone or dexamethasone, can be given intramuscularly or intravenously in single or two divided doses^{1,18,19}. Once the severity of the disease is brought under control, the maintenance therapy for 7-14 days can be done by institution of oral prednisolone at a dose of 1mg to 3mg/kg/day or equivalent dose of betamethasone in single or two divided doses. Cases of hereditary angio-oedema (HAE) show poor response to conventional treatment modalities. Parenteral or oral antihistamines, corticosteroids or even adrenaline is of little/no help in such cases^{20,21}. However, all patients with HAE do not require treatment. Treatment strategy can be planned as "short term prophylaxis" and "long term prophylaxis". For acute attacks before or after surgery, infusion of purified inhibitor helps. Long-term control of the disease can be achieved by any one of the drugs e.g. danazol, fresh frozen plasma concentration, stanozolol, epsilon amino caproic acid (EACA) or tranexamic acid^{20,21}. However, their potential toxicities limit their long-term safe use.

Urticaria in infants and children, particularly when recurrent and chronic, causes lots of anxiety and apprehension in their parents. Explaining the benign nature of the disease, presumptive precipitating factors and their avoidance help to allay anxiety of the parents. Hence, reassurance and counseling of the parents form the 'cornerstone of management' of urticaria and angio-oedema in infants and children^{1,22}.

Points to remember

1. *Aetiological factors are more readily identifiable in infants and children.*

2. *Mostly acute urticaria is seen in children as compared to frequent occurrence of chronic urticaria in adults.*
3. *Infections are very important cause of urticaria in paediatric age group.*
4. *Various food articles e.g., cow milk, fish, egg, peanuts are commonly implicated as compared to food additives playing more important role in adult urticaria.*
5. *In children, drugs are not that important a cause for urticaria.*

References

1. Warin RP, Champion RH. Urticaria and angioedema. In : Ruiz Maldonado I Parish LC, Beare JM, eds. Textbook of Pediatric Dermatology. Philadelphia, Grune & Stratton, 1989: pp 600-611.
2. Hannuksela M. Urticaria in children, Semin Dermatol 1987; 6 : 321-325.
3. Champion RH, Roberts SOB, Carpentier RG, Roger JH. Urticaria and angioedema: a review of 554 patients. Br J Dermatol 1969; 81 : 588-597.
4. Black AK, Champion RH. Urticaria, In : Champion RH, Burton JL, Burns JL, et al (eds). Textbook of Dermatology, 6th edn. Oxford : Blackwell Science, 1998 : pp 2113-2139.
5. Champion RH. Urticaria : then and now. Br J Dermatol 1988 : 427-436.
6. Hamrick HJ, Moore GW. Giardiasis causing urticaria in a child. Am J Dis Child 1983; 137 : 761-763.
7. Twarog FJ. Urticaria in childhood : pathogenesis and management. Pediatr Clin N Am 1983; 30 : 887-898.
8. Mortureux P, Leaute-Labreze C, Legrain-Lifermann V, Lamireau T, Sarlangue J, Taieb A. Acute urticaria in infancy and early childhood. A prospective study. Arch Dermatol 1998; 134 : 319-323.
9. Hamann CP. Natural rubber latex protein sensitivity in review. Am J Contact Derm 1993; 4 : 4-21.
10. McMahon BJ, Helminiak C, Wainwright RB. Frequency of adverse reaction to hepatitis B vaccine in 43618 persons. Am J Med 1992; 92 : 254-256.
11. James JM, Burks W, Roberson PK, Sampson HA. Safe administration of the measles vaccine to children allergic to eggs. N Engl J Med 1995; 332 : 1262-1266.
12. Sharma VK, Dhar S. Clinical pattern of cutaneous drug eruptions among children and adolescents in North India. Pediatr Dermatol 1995; 12 : 178-183.
13. Kauppinen K, Juntunen K, Lanki H. Urticaria in children. Allergy 1984; 39 : 469-472.
14. Legrain V, Taib A, Sage T et al. Urticaria in infants : a study of 40 patients. Pediatr Dermatol 1990; 7 : 101-107.
15. Ghosh S, Kanwar AJ, Kaur S. Urticaria in children. Pediatr Dermatol 1993; 10 : 107-110.
16. Harris A, Twarog FJ, Geha RS. Chronic urticaria in childhood : natural course and etiology. Ann Allergy 1983; 51 : 161-165.
17. Juhlin L. Recurrent urticaria: clinical investigation of 330 patients. Br J Dermatol 1981; 140 : 369-380.
18. Kennard CD, Ellis CN. Pharmacologic therapy for urticaria. J Am Acad Dermatol 1991; 25 : 176-189.
19. Bochner BS, Lichtenstein LM. Anaphylaxis. N Eng J Med 1991; 324 : 1785-1790.
20. Agostini A, Cicardi M. Hereditary and acquired C1-inhibitor deficiency : biological and clinical characteristics in 235 patients. Medicine 1992; 71 : 206-215.
21. Wall RT, Frank M, Hahn M. A review of 25 patients with hereditary angioedema requiring surgery. Anesthesiology 1989; 71 : 309-311.
22. Mahmood T, Janniger C. Childhood urticaria. Cutis 1993; 52 : 78-80.

DERMATOLOGY**ADVERSE CUTANEOUS DRUG REACTIONS IN CHILDREN***** Devinder Mohan Thappa****** Shivaswamy KN**

Abstract: *Adverse cutaneous drug reactions (ACDRs) are caused by a wide variety of agents. They are responsible for approximately 3% of all disabling injuries during hospitalization. Many of the commonly used drugs have reaction rates of over 1%. The adverse reactions may vary from simple maculopapular rash to fatal toxic epidermal necrolysis. Morphology and pattern of cutaneous adverse drug eruptions and the drugs producing them are changing every year with advent of newer drugs and newer diseases.*

Key words: *Drug rash, Steven Johnson syndrome, Toxic epidermal necrolysis, dermatological emergency*

Adverse cutaneous drug reactions (ACDRs) are caused by a wide variety of agents. They are responsible for approximately 3% of all disabling injuries during hospitalization. Many of the commonly used drugs have reaction rates over 1%¹. There is a wide spectrum of cutaneous adverse drug reactions varying from transient maculopapular rash to fatal toxic epidermal necrolysis (TEN)^{2,3}. Patterns of cutaneous adverse drug eruptions and the drugs responsible for them are changing every year.

A drug may be defined as a chemical substance or combination of substances, administered for the investigation, prevention or treatment of diseases or symptoms, real or imagined¹. Adverse reactions may be defined as an undesirable clinical manifestations resulting from administration of a particular drug: this includes reactions due to overdose, predictable side effects, and unanticipated adverse manifestations⁴.

Epidemiology

There is scanty published data on the adverse drug reactions in children⁵. Although drug metabolism differs in young children and adults, information on efficacy and toxic effects of drugs is rarely available. Children are not generally included in clinical trials and therefore, drugs are prescribed based on data derived from trials done in adults⁵. The incidence of adverse drug reactions in children varies from 1.5% (in Italy) to 4.5% (in Netherlands)^{5, 6}. Adverse drug reactions in general pediatric out patients were recorded in 4.7% of cases in a study⁷. Pudukadan and Thappa found only 6 children with ACDR amongst 90 cases of ACDR recorded in two years (2001-2003) at our institute⁸. The most common eruptions observed were fixed drug eruption (31.1%) and maculopapular rash (12.2%), and the most common causative drugs were co-trimoxazole (22.2%) and dapsone (17.7%).

Sharma and Dhar⁹ studied cutaneous drug eruptions and the incriminating drugs in 50 children and adolescents up to 18 years of age (34 or 65% boys, 16 or 32% girls) at PGIMER, Chandigarh, in north India. Thirteen (26%) patients were found to have a maculopapular rash,

* Professor and Head,

** Senior Resident,
Department of Dermatology and STD,
Jawaharlal Institute of Postgraduate Medical
Education and Research (JIPMER),
Pondicherry - 605 006, India

11 (22%) fixed drug eruption (FDE), 10 (20%) erythema multiforme (EM), 6 (12%) toxic epidermal necrolysis (TEN), 5 (10%) Stevens-Johnson syndrome (SJS), 3 (6%) urticaria, and 2 (4%) erythroderma. The incubation period for maculopapular rashes, SJS and TEN due to commonly used antibiotics and sulfonamides was short, a few hours to two to three days, reflecting reexposure, and for drugs used sparingly such as antiepileptics and antituberculosis agents, was approximately one week or more, suggesting a first exposure. Antibiotics were responsible for cutaneous eruptions in 27 patients, followed by antiepileptics in 17, analgin in 4, and metronidazole and albendazole in 1 each. Cotrimoxazole, a combination of sulfamethoxazole and trimethoprim, was the most common antibacterial responsible for eruptions (11 patients), followed by penicillin and its semisynthetic derivatives (8 patients), sulfonamide alone (3 patients), and other antibiotics (4 patients). Antiepileptics were the most frequently incriminated drugs in EM, TEN, and SJS.

Multiple medical problems increase the chance of developing adverse drug eruptions⁸. Adverse drug reactions amongst pediatric patients are influenced by several factors like prolonged hospital stay, the classes of drugs used and polypharmacy.

Characteristics of drug eruptions

These eruptions may closely mimic other skin disorders¹⁰. Following features characterize drug eruptions:

1. There is a history of drug intake preceding the eruption. The history of drug intake must include all systemic drugs, nonprescription drugs, home remedies and topical medications.
2. Drug eruption is sudden in onset.

3. Generalized eruption is often pruritic.
4. Eruption is bilateral and symmetrical; exception to this is fixed drug eruption.
5. Regression of eruption occurs on withdrawal of drug.
6. Similar type of rash recurs on re-exposure to the same or similar drug.

Pathogenesis

Undesirable cutaneous or mucocutaneous reactions to systemically absorbed drugs occur through three mechanisms (Table 1)¹¹.

1. **Non-immune mechanisms:** They include drug induced hemolysis (G_6PD deficiency), mast cell degranulation (codeine, radiocontrast media), exacerbation of disease (psoriasis by lithium or beta blocker), drug deposition in skin, alopecia etc.
2. **Immune mechanisms:** All the four hypersensitivity mechanisms may be involved.

Type I – IgE dependent reactions cause urticaria, pruritus, bronchospasm and laryngeal oedema within minutes, hours or days.

Type II – Cytotoxic reactions may cause thrombocytopenia.

Type III – Immune complex dependent reactions result in serum sickness, urticarial or leukocytoclastic vasculitis within a week or so.

Type IV – Cell mediated immune response may lead to eczematous and other types of eruptions in 3 to 4 weeks time.

3. **Miscellaneous mechanisms:** Under this comes, Jarisch-Herxheimer reaction and infectious mononucleosis like reaction.

Table 1. Classification of pathogenetic mechanisms of adverse drug reactions

1. Non-immunological

Predictable

Overdosage
Side-effects
Cumulative effects
Delayed toxicity
Facultative effects
Drug interactions
Metabolic alterations
Teratogenicity
Non-immunological activation of effector pathways
Exacerbation of disease
Drug-induced chromosomal damage

Unpredictable

Intolerance
Idiosyncrasy

2. Immunological (unpredictable)

IgE-dependent drug reactions
Immune complex-dependent
Cytotoxic drug-induced reactions
Cell-mediated reactions

3. Miscellaneous

Jarisch-Herxheimer reactions
Infectious mononucleosis-ampicillin reaction

possible, if there is only a reasonable time relationship between the drug and adverse cutaneous event but information on de- or re-challenge is unavailable or unclear¹¹.

The appearance of the eruption may provide some clues to its cause^{6,10}. Always keep in mind the fact that drug eruptions are great imitators of other skin diseases.

Types of drug eruptions

1. Maculopapular eruptions (occur within one week)
2. Urticarial eruptions
3. Annular erythemas like pityriasis rosea
4. Serum sickness
5. Acneiform eruptions
6. Lupus and dermatomyositis like eruptions
7. Scleroderma like reactions
8. Lichenoid eruptions
9. Pityriasis rosea like eruptions
10. Phototoxic and photoallergic eruptions
11. Vesicobullous eruptions
12. Pustular eruptions
13. Eczematous eruptions
14. Pseudolymphomatous eruptions
15. Acanthosis nigricans like eruption
16. Ichthyosiform eruptions
17. Drug induced hair changes (alopecia or hypertrichosis), nail changes (Mee's lines) or oral changes (stomatitis)
18. Skin pigmentation
19. Vasculitic eruptions
20. Hypersensitivity syndrome reaction
21. Fixed drug eruptions
22. Erythroderma
23. Erythema multiforme (EMF)
24. Stevens Johnson syndrome (SJS)
25. Toxic epidermal necrolysis (TEN)

Clinical features and types of drug eruptions

The drugs most often responsible for the eruptions are antimicrobials and antipyretic / anti-inflammatory analgesics¹⁰. These drug eruptions can be classified into: **definite**, if both dechallenge (resolution of rash after drug withdrawal) and rechallenge (oral or patch test, or intradermal test as appropriate) are positive; **probable**, if only dechallenge is positive but rechallenge is negative or is not done; and

Important patterns of reactions are given in the Table 2.

Hypersensitivity syndrome reaction (HSR):

This is a rare but serious syndrome. It occurs in approximately 1 in 10000 exposures⁶. The syndrome is characterized by initial onset of fever followed by skin rash and possible involvement of internal organs. HSR occurs most often on the first exposure to the drug. Therefore it can occur at any age. There is a delayed onset of 7-28 days after the initial exposure to the drug and this depends partly on the drug. The most common drugs implicated in HSR are anticonvulsants (phenytoin, carbamazepine, and phenobarbital),

sulfonamides, procainamide, minocycline etc. It starts with fever and malaise, followed by swelling of face and erythema, which spread to involve whole body. Pharyngitis and cervical lymphadenopathy are often early manifestations. This is usually followed by exanthematous skin rash that starts over the face and then spreads downwards. A smaller group of patients will develop a severe reaction in the form of erythema multiforme (EMF), Stevens Johnson syndrome (SJS) or Toxic epidermal necrolysis (TEN) as a part of HSR. In children, there is an interesting 'bandit' appearance with involvement around the eyes and on the hands and feet of severe blistering

Table 2. Common patterns of drug reactions

| | |
|---|-------------------------------------|
| Cutaneous eruptions | Quinine and derivatives |
| Penicillin | Dapsone |
| Sulphones - Dapsone | Erythromycin |
| Phenytoin | Barbiturates |
| Antituberculous drugs | Mebendazole |
| Antimalarials | Exanthematic eruption |
| Sulphonamide | Penicillin |
| Penicillamine | Digitalis |
| Thiazide | Ampicillin |
| Amoxicillin | Phenothiazines |
| Ampicillin | Sulphonamides |
| Erythema multiforme | Barbiturates |
| Penicillin and other semi-synthetic penicillins | Atropine |
| Chloramphenicol | Isoniazid |
| Acetylsalicylic acid | Urticaria and angio – oedema |
| Codeine | Salicylate |
| Isoniazid | Hydantoin |
| Phenytoin | Furazolidone |
| Barbiturates | Sulphonamides |
| Rifampicin | Penicillin |
| Ibuprofen | Sera and vaccines |
| Sulphonamides | Sera and vaccines |
| Fixed drug eruption | Cephalosporins |
| Sulphonamides | Toxoids |
| Salicylates | Enzymes |
| Codeine | Polypeptide hormones |
| Oxyphenbutazone | |

and epidermal necrosis. This is a form of SJS, which is usually not seen in adults. Internal organ involvement may come as late as 1-2 weeks. The most common inflammatory reaction is hepatitis followed by renal involvement. Other less common, but important internal reactions includes that of central nervous system (encephalitis, aseptic meningitis), lungs (interstitial pneumonitis, respiratory distress syndrome), myocarditis, and pancreatitis, etc.⁶

Fixed drug eruption: It differs from other eruptions in that it occurs and then recurs at fixed sites¹⁰. Single or multiple circular or oval erythematous macule(s) or plaque(s) develop with burning or stinging sensation. These lesions sometime develop into bullous lesions and when heal leave behind slate gray coloured pigmentation. Mucocutaneous junctions are commonly affected.

Erythroderma: It is a generalized erythema, infiltration and scaling of the skin (involving more than 90% of the surface area of the body)¹⁰. It may be a manifestation of drug eruption but usually occurs due to dermatological disorders like psoriasis, contact dermatitis, pityriasis rubra pilaris, etc.

Erythema multiforme: Erythema multiforme is characterized by many types of lesions including urticaria, target lesions (iris lesions or bulls-eye lesions) and vesicles and bullae, bilaterally symmetrically over acral areas of the body¹⁰. They may also involve mucous membranes.

Steven Johnson syndrome: It is severe form of erythema multiforme associated with constitutional symptoms (fever) and visceral organ involvement e.g. kidneys¹⁰. Both the skin as well as mucous membranes are involved.

Toxic epidermal necrolysis (TEN): The term **toxic** referred to a presumed toxin responsible for the prodrome and the eruption, **epidermal** to the presence of significant epidermal damage and **necrolysis** for the pathologic findings of necrosis

and clinical findings of epidermolysis¹⁰. It is a potentially life threatening, severe mucocutaneous reaction pattern characterized by fever, systemic toxicity, erythema and tenderness of skin followed by flaccid bullae formation resembling a burn case. Nikolsky's sign is positive. Mortality from TEN is 11 to 33%.

Diagnosis

Diagnosis is basically based on suspicion and history of drug intake. A general rule of thumb is that drugs started within one week of the onset of the eruption are the most suspects¹⁰.

The proper diagnosis of drug eruptions requires a stepwise approach¹². These are making the best diagnosis of eruption, determining the differential diagnosis of the event and the causes, finding every drug that patient was exposed to and estimating the probability that the drug was responsible for the reaction^{6,12}.

Making a diagnosis of skin eruption:

The first step in managing an ACDR is to make the proper diagnosis. Reactions in the skin can be diagnosed at three levels. These are based on the determination of a specific morphology of skin disease or syndrome.

Morphology: The morphology of an ACDR is usually exanthematous, urticarial or blistering. Sometimes, it is not possible to be more specific. Synonyms used for exanthematous reactions are morbiliform, scarlatiniform or toxic erythema. These reactions can progress to erythroderma or exfoliative dermatitis. Urticarial reactions may represent simple urticaria or be in association with other symptoms or pathological changes, or they may represent urticarial vasculitis or serum sickness like reaction. Until further diagnostic steps are taken, the urticarial morphology is often the only clue to the diagnosis.

Skin disease: Specific diseases would include eruptions as diverse as fixed drug eruptions

(FDE), acute generalized exanthematous pustulosis (AGEP) or urticaria. These are based on cutaneous findings and the specific diagnosis relates to a purely cutaneous manifestation of a drug eruption without internal organ involvement.

Syndromes: There are many syndromes that fall into the hypersensitivity reaction category and these are associated with cutaneous manifestations as well as internal organ involvement. Serum sickness like reaction (SSLR) and hypersensitivity syndrome reaction (HSR) are two examples^{6,12}.

Differential diagnosis

The second step in diagnosing a drug reaction requires an evaluation of differential diagnosis of the rash or syndrome⁶. Etiologies that may enter into discussion include viral exanthems (infectious mononucleosis, human parvovirus infection, etc), bacterial infections, Kawasaki's disease and collagen vascular diseases. For erythema multiforme, the common alternative causes include herpes virus and mycoplasma infection.

Treatment

Clearly, prevention is better than cure^{1, 6, 13}. Drugs implicated in a previous reaction should be avoided. In case of suspected penicillin allergy, an alternative antibiotic, such as erythromycin should be substituted. The approach to treatment of an established presumed drug eruption obviously depends on the severity of the reaction. For minor conditions, withdrawal of the suspected drug, and symptomatic therapy with emollients, topical corticosteroids and systemic antihistamines is all that is necessary. The management of TEN is perhaps best carried out in an intensive care or burns care unit. The mortality of TEN is around 20-30% despite intensive care therapy. There are both merits and demerits of using corticosteroid therapy for TEN.

Some authorities maintain that high dose steroid therapy promotes or masks signs of infection, delays healing, prolong hospital stay. Some favour its use on the basis that it reduces inflammation and keratinocyte necrosis if used early in the disease. The other modalities of treatment are intravenous immunoglobulin therapy, plasmapheresis, cyclosporine and cyclophosphamide. Supportive care such as maintenance of fluid and electrolyte balance, body temperature, nutrition, and wound care are utmost important. In case of HSR, the role of corticosteroids is still debatable, but has a definite role if kidneys are involved^{1,6,13}.

Rechallenge test may be done, once rash has settled¹⁰. However, in patients who have had urticarial, bullous or erythema multiforme-like eruptions, it can be dangerous.

Points to remember

1. *There is a history of drug intake preceding the eruption. The history of drug intake must include all systemic drugs, nonprescription drugs, home remedies and topical medications.*
2. *Drug eruption is sudden in onset. Generalized eruption is often pruritic.*
3. *Eruption is bilateral and symmetrical; exception to this is fixed drug eruption.*
4. *Regression of eruption occurs on withdrawal of drug.*
5. *Similar type of rash recurs on re-exposure to the same or similar drug.*

References

1. Breathnach SM. Drug reactions. In: Champion RH, Burton JL, Burns DA, Breathnach SM, eds. Rook/Wilkinson/Ebling Textbook of Dermatology, 6th edn., Oxford: Blackwell Science Ltd, 1998: pp 3349-3517.
2. Shapiro S, Slone D, Siskind V, et al. Drug rash with ampicillins and other penicillins. Lancet 1969; 2: 969-972.

3. Baer RL, Witten VM. Year Book of Dermatology 1960-61 series (Drug eruptions). Chicago: Yearbook Medical Publishers, 1961; pp 9-37.
4. Scott HD, Thacher-Renshaw A, Rosenbaum SE, et al. Physician reporting of drug reactions. Results of Rhode Island Adverse Drug Reaction Reporting Project. JAMA 1990; 263: 1785-1788.
5. Menniti-Ippolito F, Raschetti R, Da Cas R, et al. Active monitoring of adverse drug reactions in children. Lancet 2000; 355:1613-1614.
6. Shear NH, Landau M, Shapiro LE. Hypersensitivity reactions to drugs. In: Harper J, Oranje A, Prose N, eds. Textbook of Paediatric Dermatology. 1st edn., Oxford: Blackwell Science. 2000; pp 1743-1752.
7. Kramer MS, Hutchinson TA, Flegel KM, et al. Adverse drug reactions in general paediatric out patients. J Pediatr 1985; 106:305-310.
8. Pudukadan D, Thappa DM. Adverse cutaneous drug reactions: Clinical pattern and causative agents in a tertiary care center in South India. Indian J Dermatol Venerol Leprol 2004; 70: 20-24.
9. Sharma VK, Dhar S. Clinical pattern of cutaneous drug eruption among children and adolescents in north India. Pediatr Dermatol. 1995;12(2): 178-183.
10. Thappa DM. Urticaria, Pruritus and Drug Eruptions. In: Textbook of Dermatology, urticaria, Pruritus and Drug Eruptions, Venereology and Leprology, 2nd edn., New Delhi: Elsevier, 2005: pp 193-198.
11. Khopkar U. Reporting of drug eruptions: The National Pharmacovigilance Program. Indian J Dermatol Venereol Leprol 2005; 71:1-2.
12. Shear NH. Diagnosing cutaneous adverse reaction to drugs. Arch Dermatol 1990; 126: 94-97.
13. Renfro L, Grant-Kels JM, Daman LA. Drug induced toxic epidermal necrosis treated with cyclosporine. Int J Dermatol 1989; 28:441-444.

NEWS AND NOTES

**1st Asia Pacific Congress on Pediatric Critical Care
with
7th National Congress on Pediatric Critical Care
Annual Conference of IAP Intensive Care Chapter
Organised by IAP, Pune Branch**

Date: 21st, 22nd, 23rd October, 2005

Venue: Bharati Vidyapeeth Deemed University Medical College, Pune – 411 043.

Address for Correspondence: Dr.Sanjay Lalwani, 63/2B, Kamia Heritage, Opp.Ashwamegh Auto, Pune Satara Road, Pune – 411 009. Mobile: 9373314322, Email: lalwani@necpccpune.com, medvents@necpccpune.com

**MP PEDINEOCON 2005 - 'SPARSH'
36th Annual State Conference of NNF**

Venue: Hotel Narmada Jacksons, Civil Lines, Jabalpur,

Date: 5th and 6th November 2005

For further details contact: Dr. Girish Budhrani, Satyam, 6 Bose Colony, Rampur, Jabalpur, MP. Ph. 0761-2561386 (C), 5036202 (R). Fax: 0761-2625929, Mobile: 9425387700, Email: drgirishbudhrani@yahoo.co.in

DERMATOLOGY

CHILDHOOD BACTERIAL SKIN INFECTIONS

* **Sangeeta Amladi**

Abstract: Bacterial skin infections in children are never to be taken lightly. They may spread horizontally to form larger lesions. The disease can move vertically to involve soft tissues and bones. Blood spillover leads to septicaemia and disaster. Skin infections may be a marker of immune deficiency states. In pediatric age group bacterial skin infection are the most common infections. The human body is host to millions of bacteria living as commensals on the skin. Occasionally overgrowth of these organisms may cause minor infections of the skin and appendages. Among these staphylococcus aureus and streptococcus pyogenes are common pathogenic bacteriae. These infections are common in tropical climates, in summer months, in conditions of overcrowding and poor hygiene, and also in immunosuppressed states such as steroid therapy or HIV infection.

Keywords: Pyodermas, Staphylococcus, Streptococcus

Bacterial infections of the skin or pyodermas are among the most common infections in the pediatric age group. The human body is host to millions of bacteria living as commensals on the skin. These include Staphylococcus, Micrococcus, Corynebacterium, Brevibacterium and Acinetobacter species¹. Occasionally overgrowth of these organisms may cause minor

infections of the skin and appendages. However, the common pathogenic bacteria giving rise to childhood bacterial infections are Staphylococcus aureus and Streptococcus pyogenes². All bacterial infections are commoner in tropical climates, in summer months, in conditions of overcrowding and poor hygiene, and also in immunosuppressed states such as steroid therapy or HIV infection. The present article will discuss common and rare presentations of staphylococcal and streptococcal infections in children.

Classification

| | |
|--------------------------------|--|
| A. Primary | Impetigo Ecthyma Folliculitis Periporitis Cellulitis Erysipelas |
| B. Secondary | Scabies Eczema and dermatitis |
| C. Toxin-mediated conditions | Staphylococcal scalded skin syndrome Toxic shock syndrome Scarlet fever |
| D. Exacerbation of dermatoses: | Atopic dermatitis Guttate psoriasis |

Primary bacterial infections

Impetigo

This is a common superficial pyoderma which is characterised by infection and inflammation of epidermis, typically seen in preschool and schoolgoing children. There are two main types: impetigo contagiosum and bullous impetigo¹⁻³.

* Professor of Dermatology
T N Medical College and B Y L Nair Hospital
Mumbai 400008, India

Impetigo contagiosum (Tilbury Fox): This is the crusted variety and may be caused by either staphylococci or streptococci, or even both together. The infection may follow minor scratches or insect bites. The anterior nares may be the reservoir for the infection leading to recurrent episodes. The lesion is initially a small red macule, which develops into a vesicopustule. This ruptures rapidly to leave behind a crusted seropurulent oozing area of a typical yellowish honey colour (Fig. 1). Multiple lesions develop and may coalesce on areas such as the face, especially around the nose and mouth. Buttocks and limbs may also be involved. Local lymphadenopathy may develop, more commonly with streptococcal rather than staphylococcal impetigo.

Bullous impetigo: This is caused by *Staphylococcus aureus*. It is distributed similarly as in impetigo contagiosum and may also occur in neonates. The initial red macules develop in to larger vesicles or bullae, which are fragile and rupture leaving annular or circinate erythematous scaly areas.

Lesions of impetigo heal rapidly leaving behind no sequelae, except mild transient post inflammatory pigmentation. Impetigo can be widespread in the setting of atopic dermatitis or scabies with secondarily impetiginized lesions. Patients with multiple or recurrent infections are more likely to be contagious to other children. Streptococcal impetigo may be followed by post-streptococcal acute glomerulonephritis, urticaria, erythema multiforme or scarlet fever, but not rheumatic fever¹.

In mild and localized infection, topical antibiotics such as mupirocin, sodium fusidate or even neomycin and bacitracin may be sufficient. Resistance to topical therapy may be minimized by judicious short term use. Oral antibiotics such as erythromycin and cloxacillin may be used for more severe infection. Removal

of crusts using potassium permanganate 1:10000 soaks is of help. Nasal carriage of *Staphylococci* causing recurrent impetigo is managed with daily application of mupirocin or sodium fusidate ointment in the anterior nares for a fortnight.

Ecthyma

Ecthyma is a deeper infection caused mainly by Group A streptococci, but also may be due to *Staphylococcus aureus*, or both together⁴. The typical feature of this infection is the formation of a thick crust following small pustules on an erythematous base. It is difficult to detach this crust, and underlying it is an irregular ulcer with purulent discharge. Lesions are seen mainly on the lower limbs and buttocks. At any given time there may be few lesions, however, new ones keep developing through auto-inoculation. Healing may take a few weeks and leave behind scarring. Ecthyma is treated with topical and oral antibiotics similar to impetigo. General measures to improve hygiene and nutrition are always helpful.

Folliculitis/Furuncle

This term refers to pyogenic infection of the follicles. It may be superficial or deep. Superficial folliculitis¹ is seen more commonly in children on the scalp and face (Bockhart's impetigo) as yellow pustules on an erythematous base, and may be recurrent and chronic. Folliculitis of the beard area (*Sycosis barbae*) may be seen in postpubertal males following shaving. Chronic and recurrent folliculitis of the legs (*Dermatitis cruris pustulosa et atrophicans*) has been observed in young males in India^{1,3}. The pustules are seen symmetrically on the thighs and shins, grow *Staphylococcus aureus* and heal with atrophy and scarring. Treatment is with topical and oral antibiotics.

Furuncles (boils) are acute staphylococcal infections leading to abscesses of the hair follicle.

They are not as common in childhood, however mechanical trauma and malnutrition may be predisposing factors. A furuncle first appears as a small reddish inflammatory nodule, then becomes pustular and necrotic, and heals after discharge of necrotic and purulent material leaving behind a scar. The lesion is extremely tender. Few or multiple lesions may be seen, and may be accompanied by fever or constitutional symptoms. Recurrent episodes may be due to nasal or perineal carriage of staphylococci. Furuncles need to be treated with oral antibiotics and may require in addition anti-inflammatory drugs.

Perioritis

This is an infection of the sweat glands, commonly seen on the forehead, face and scalp in young children in the hot summer months. Lesions are erythematous, not very tender or pustular, and are usually found in a bed of miliaria rubra (prickly heat).

Cellulitis/Erysipelas

Both these terms refer to deeper infection of the skin, subcutaneous tissue and often the lymphatics. Cellulitis and erysipelas are caused by *Strep. pyogenes*, but may be rarely due to *Staph aureus*⁵. Lesions are characterised by redness, swelling, pain and tenderness. The margins are sharply defined and elevated. Lesions tend to heal with appropriate therapy leaving behind post-inflammatory pigmentation and scaling. Erysipelas is known to follow a streptococcal sore throat and typically presents on the face in children. Cellulitis may follow a history of trauma or insect bite, and may be seen anywhere on the body, but commonly the limbs. Oral antibiotics and anti-inflammatory drugs are required.

Streptococcal vulvovaginitis and perianal infection

Vulvovaginitis in prepubertal girls may be due to *Strep. pyogenes*. There is soreness and

irritation of the genital area with severe erythema and purulent discharge⁶. Dysuria may be a feature. Perianal infection with *Strep. pyogenes* presents similarly with redness, inflammation, irritation and pain on passing stools⁷. It may accompany vulvovaginitis in girls. Oral and topical antibiotic therapy is recommended.

Secondary bacterial infection

Pruritic conditions in children such as scabies and eczemas are often complicated by the development of secondary pyogenic infection and impetiginization mainly due to *Staph. aureus*. Management of the infection with topical and oral antibiotics helps to hasten the healing of the original condition.

Toxin-mediated conditions: Staphylococcal Scalded Skin Syndrome

This is a condition resulting from epidermolytic toxins released by the staphylococci. Typically seen in young children, fever and irritability are followed by a diffuse erythematous rash⁸. The skin is tender to touch, and the child cries on handling. Superficial flaccid blisters develop and rupture leaving painful raw areas. The condition heals within two weeks of intravenous antibiotic therapy with scaling, leaving behind no sequelae. Swabs from the blister fluid do not grow staphylococci. Most children will give a preceding history of staphylococcal infection either cutaneous or respiratory.

Toxic shock syndrome

This is a severe condition characterised by the acute onset of fever, vomiting, a widespread erythematous macular rash, mucosal erythema and edema, multisystem involvement with circulatory shock. It was earlier thought to be exclusively associated with the use of tampons in menstruating women leading to staphylococcal infection⁹. IV antibiotics and supportive ICU management are required.

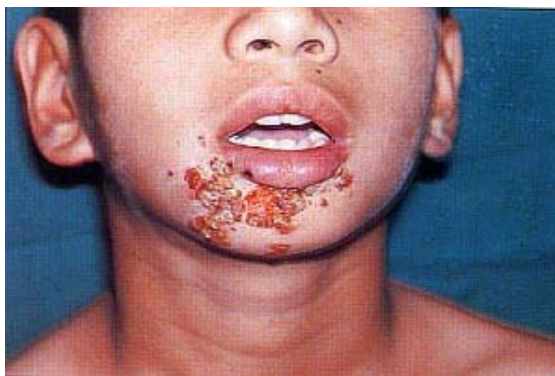

Fig. 1 Honey coloured crusts of impetigo contagiosum

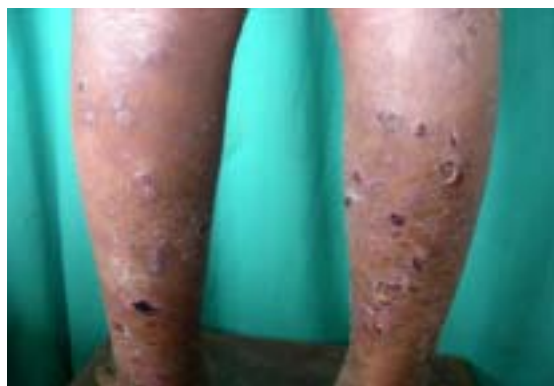

Fig. 2 Deeper crusted lesions of ecthyma with eroded areas on the legs

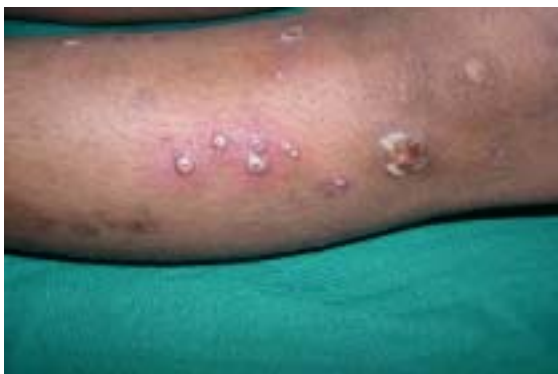

Fig. 3 Follicular pustules on an erythematous base with central necrosis and crust

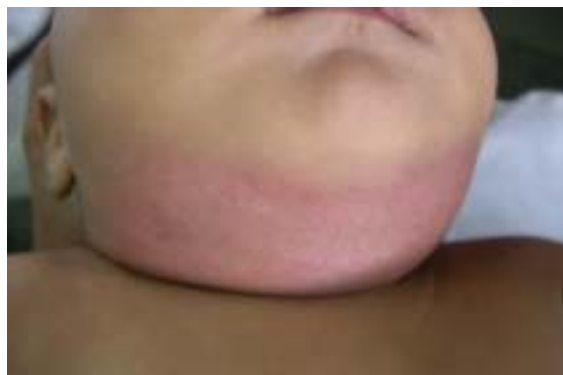

Fig. 4 Cellulitis on the neck showing a tender erythematous inflamed swelling with well defined margins

RED disorder

Recalcitrant erythematous desquamating (RED) disorder is similar to toxic shock syndrome in AIDS patients¹⁰. It is a multisystem disease with a prolonged course associated with fever, hypotension, macular erythematous rash and mucosal erythema. *Staphylococcus aureus* has been isolated from most patients. Management is similar to that of toxic shock syndrome.

Scarlet fever

This is due to the release of a pyrogenic exotoxin from *Strep. pyogenes* called erythrogenin. Scarlet fever is not common in the tropics although it

occurs throughout the world¹¹. Patients present with fever, constitutional symptoms, severe tonsillitis and an erythematous rash appearing on the second day. Initially punctate, the erythema later becomes streaky giving a flushed appearance. It subsides with scaling within 7-10 days. Penicillin or other antistreptococcal antibiotics should be used.

Exacerbation of dermatoses

It is a well known fact that staphylococcal colonisation of the skin in patients of atopic dermatitis is associated not only with increased severity and flares of the disease, but also with recurrences of the eczematous episodes¹². Guttate

psoriasis is a morphological variant of psoriasis typical to childhood, associated with an eruption of multiple small 'guttate' psoriatic lesions following an episode of streptococcal sore throat¹³.

Points to remember:

1. *Bacterial skin infections in children are never to be taken lightly.*
2. *They may spread horizontally to form larger lesions.*
3. *The disease can move vertically to involve soft tissues and bones.*
4. *Spillover into blood leads to septicaemia and disaster.*
5. *Skin infections may be a marker of immune deficiency states.*

References

1. Hay RJ, Adriaans BM. Bacterial infections. In: Rooks Textbook of Dermatology, T Burns, S Breathnach, N Cox, C Griffiths, eds. 7th edn Blackwell Science Oxford 2004; pp 27.1-27.44.
2. Resnick SD. Staphylococcal and streptococcal skin infections, pyoderma and toxin-mediated syndromes. In: Textbook of Pediatric Dermatology, J Harper, A Oranje, N Prose, eds. 1st edn Blackwell Science Oxford 2000; pp 369-383.
3. Singh G, Kaur V, Singh S. Bacterial infections. In: IADVL Textbook and Atlas of Dermatology, RG Valia, AR Valia, eds. 2nd edn, B I Publications, Mumbai 2001; pp 190-214.
4. Kelly C, Taplin D, Allen AM. Streptococcal ecthyma. Arch Dermatol 1971;103:306-310
5. Bernard P, Bedane C, Mournier M et al. Streptococcal cause of erysipelas and cellulitis in adults. Arch Dermatol 1989;125:779-782
6. Schwartz RH, Wientzen RL, Barsanti RG. Vulvovaginitis in prepubertal girls. The importance of group A streptococcus. South Med J 1982;75:446-447
7. Marks VJ, Maksimik M. Perianal streptococcal cellulitis. J Am Acad Dermatol 1988;18:587-588.
8. Curran JP, Al-Sahili FL. Neonatal staphylococcal scalded skin syndrome: massive outbreak due to an unusual phage type. Pediatrics 1980;66:285-290
9. Bach MC. Dermatological signs in toxic shock syndrome. J Am Acad Dermatol. 1983;8:343-347.
10. Cone LA, Woodward DR, Byrd RG et al. A recalcitrant erythematous desquamating disorder associated with AIDS. J Infect Dis 1992;168:638-643
11. Bialecki C, Feder NM, Grant-Kels JM. The six classical childhood exanthems. A review and update. J Am Acad Dermatol 1989;21:891-903.
12. Lever R. Microbiology of atopic dermatitis. In: Textbook of Pediatric Dermatology, J Harper, A Oranje, N Prose, eds. 1st Edn, Oxford Blackwell Science, Oxford 2000; pp 194-197
13. De Waard-Van der Spek F, Oranje A. Psoriasis. In: Textbook of Pediatric Dermatology, J Harper, A Oranje, N Prose, eds. 1st Edn, Oxford Blackwell Science, Oxford 2000; pp 1657-1663

NEWS AND NOTES

1st National Meet on Ethical & Medico-legal Issues & 2nd Maharashtra State ITCF Conference

Venue: Maharashtra, **Date:** 11th November 2005

Address for Correspondence: Dr. Satish Tiwari, Organizing Secretary, Yashodanagar No.2, Amravati, Maharashtra – 444 606. Ph: (0721) 2672252, 5612680. Email: ati_drtiwari@sancharnet.in

DERMATOLOGY**PEDICULOSIS AND SCABIES IN CHILDREN****Shahbaz A. Janjua**

Abstract: *Scabies, followed by pediculosis, is the commonest cause for itchy skin disorders in the tropics. Apart from the climatic conditions, the poor living conditions seem to contribute towards this malady. One has to remember that these diseases have protean manifestations in infants and children, hence they are difficult to diagnose.*

Key words: *Ectoparasitosis, Sarcoptes scabiei, pediculus capitis*

Pediculosis and scabies are the most prevalent parasitic infestations of humans worldwide. Both the conditions are caused by ectoparasites sharing a common characteristic feature of causing intense pruritus. Both are treated by the topically administered chemical agents, preferably, 1 % permethrin, but growing resistance to the topical agents remains a challenge for the treating physicians and dermatologists.

The lice are obligate human ectoparasites. The three lice species that infest humans are; *Pediculus humanus capitis*, *Phthirus pubis*, and *Pediculus humanus corpus*. They are known as head louse, pubic louse and body louse respectively. All three types are transmitted by close person to person contact. The body louse infestation preferentially affects the homeless and displaced, and remains a major vector of diseases

such as typhus, trench fever, and relapsing fever, whereas pubic louse infestation often is acquired as a sexually transmitted disease. The head louse infestation, which crosses all economic and social boundaries, commonly affects young children, occurring in affluent, rural and urban schools alike. The lice that infest human beings are almost always sucking lice that live in close association with the host and lay their eggs on hair shafts or in the seams of clothing. The importance of environmental measures to prevent infestation is still a matter of controversy.

Scabies is a highly pruritic condition caused by the mite *Sarcoptes scabiei* var. *hominis*. It is transmitted mainly by direct personal or sexual contact and, less often, by contact with infested bedding or clothing. It is characterized by severe pruritus that is often worse at night and recognized by the presence of burrows on the skin and a papular eruption with excoriations. Scabies presents differently in neonates and infants causing a generalized papulovesicular eruption.

Only pediculosis capitis and scabies in young children will be discussed further in this review.

Pediculosis capitis (Head louse)

Pediculosis capitis or head louse is caused by infestation of scalp with the highly host-specific insect, *Pediculus humanus capitis*. It remains a major health problem worldwide. No age or economic stratum is immune to the head louse infestation and generally a higher prevalence is associated with crowded conditions.

The highest incidence occurs in school-aged children, primarily girls, aged 3-12 years¹.

* Dermatologist,
Ayza Skin and Research Center, Lalamusa,
Pakistan

Transmission is thought to occur through head-to-head close contact, or contact with the infested fomites such as shared headgears, hats, brushes, combs, earphones, bedding, upholstered furniture and rugs². It has been observed that transfer is optimal to hairs that are parallel and slow-moving. Hence, the most important mode of transmission remains direct head-to-head contact for a prolonged period. Infestation may be more common during warmer months³.

Life cycle: The life cycle of the head louse begins as an egg, laid near the scalp and attached firmly to a hair shaft in an egg case, also referred to as nit. The nits move distally with hair growth, and prefer an environment that is at least 82° F and 70% humidity. They are readily identified by the naked eye on clinical inspection and can be differentiated from hair casts, dandruff, and dried hair spray that can be easily removed from the hair shaft (Fig 1). The embryo's central nervous system is fully developed within three to four days and it hatches as a nymph in seven to 10 days. Nine to 12 days after hatching, the nymph develops into a sexually mature male or female.

Within 24 hours of mating on the host's surface, the mature female louse begins laying seven to 10 eggs a day and repeated fertilization is not required. The head lice of both sexes have a life span of as much as 30 days and they survive only 15 to 20 hours off the host⁴. Nymphs and adult head lice take frequent blood meals, contributing to the symptoms of itching.

Clinical presentation and diagnosis: The head louse is almost always confined to the scalp hair and the presenting feature in young children is pruritus of variable severity. Sensitization or an allergic reaction to louse saliva, feces, or body parts may cause pruritus. It may take more than two weeks for the infestation to establish and cause symptoms. The infestation is diagnosed by direct visualization of the lice or viable nits, found most often on the back of the head and

neck and behind the ears. An average host carries a population of less than 20 adult lice but the diagnosis is confirmed by the presence of a single live louse. Other associated findings may include excoriations and pyoderma and possible cervical lymphadenopathy. If only nits are found, they should be examined microscopically for viable embryos.

Because adult lice prefer to avoid light, they can move quickly along hairs and cannot readily be seen on clinical examination. A bright light, a magnifying lens, and separating the hair may help inspection. However, combing through the hair with a louse comb and examining the teeth of the comb for living lice usually detects more cases than direct visualization alone⁵.

Treatment and prevention: The treatment of choice for the pediculosis capitis remains topically applied 1% permethrin⁶. Permethrin is a synthetic compound derived from pyrethrin that acts on the nerve cell membranes of the parasites causing paralysis of the exoskeletal muscles and subsequent suffocation of the lice. Permethrin is also an ovicidal. Permethrin is applied to the scalp as cream rinse after the hair is shampooed and dried. The product is rinsed out with water after 10 minutes. Surviving nits can cause reinfestation if not removed. Higher cure rates would be obtained by a second application one week after the initial usage⁷. The resistance can be treated with 5% permethrin and left on overnight under a shower cap⁶.

Pyrethrins have the same mechanism of action as permethrin. Piperonyl butoxide is added to potentiate the effect of the pyrethrin and may decrease the development of resistance.

Malathion is highly pediculicidal. It is a relatively weak organophosphate cholinesterase inhibitor that causes respiratory paralysis in arthropods. It does require an 8- to 12-hour treatment period and has an unappealing odor.

Lindane 1% shampoo had been a popular treatment but is no longer the preferred topical remedy⁶. There also appears to be some resistance of the louse to lindane.

Cotrimoxazole twice daily for three days has been reported as an effective treatment for head lice. The putative mechanism of action is on symbiotic gram-negative bacteria in the gut of the louse that are required for digestion of ingested blood products. Unfortunately, it is only effective against adult and nymphal stages but not the eggs and so prolonged courses are required⁸. According to one study, the combination of permethrin and trimethoprim-sulfamethoxazole was more effective than either agent alone⁹.

Ivermectin is an anti helminthic agent structurally similar to the macrolide antibiotics but without antibacterial activity. A single, oral dose of ivermectin (Stromectal) 200 mcg/kg repeated in 10 days has been shown to be effective in eradicating head lice^{6,10}. In humans, ivermectin has been proved effective in the treatment of onchocerciasis, loiasis, strongyloidiasis, bancroftian filariasis, and cutaneous larva migrans. The use and safety of oral ivermectin to treat pediculosis capitis in young children below 5 years has not been well studied.

Development of head lice resistance to current therapies, including lindane, permethrin, and malathion, has become a worldwide problem¹¹. According to one study 0.5% malathion lotion was the fastest-killing pediculicide and the most effective ovicide. One percent lindane shampoo was the slowest-acting pediculicide and least effective ovicide¹¹.

Some home remedies that are still used include kerosene oil, alcohol, and insecticides; but some of these can be hazardous¹².

Mechanical methods of treatment include

head shaving and wet combing. Wet combing involves combing wet hair with a specially designed comb every 3-4 days. The hair is wetted because, when exposed to water, lice are temporarily immobile and therefore easier to comb out. The duration of this treatment is 2 weeks or more. This treatment is time-consuming for parents.

Contact with untreated classmates and playmates can result in apparent treatment failure in the absence of drug resistance. There is no recent evidence that exclusion from school is effective in controlling head lice in school children. There may be benefit to separating hats, scarves, and jackets in the classroom. It is a simple step for each child to store them under his or her desk. Louse repellents may have potential to prevent reinfestation. Piperonal has been used as a pediculicide, but it also exhibits a repellent action against lice. A low-fragrance pump spray formulation of 2% piperonal was tested against body lice, and exhibited high repellency for 24 hours¹³.

For the community control of pediculosis capitis, an approach should be outlined that will screen and identify cases, educate the physicians, parents, and patients on optimal treatments, fomite control, and environmental clean-up.

Scabies

Scabies is known to mankind since middle ages and its descriptions can be found in ancient writings from the Greeks, Egyptians, Romans, and medieval Europeans. It is caused by a highly contagious mite, *Sarcoptes scabiei* which is an obligate human ectoparasite. It is characterized by intense pruritus, papular eruption, superficial burrows, excoriations and secondary infection. No sex, age or racial predilection has been noted, but scabies commonly affects infants, young children, sexually active adults, and institutionalized elderly.

Life cycle of the scabies mite: The tortoise shaped female mite is approximately 0.3 mm long and has eight legs. The male which is about half of the size of the female, mates with the female on the skin surface. After fertilization, the adult female burrows into the stratum corneum. The mite lays 2 to 3 eggs a day and dies after 5 weeks at the end of the burrow¹⁴. Larvae from these eggs hatch after approximately 2 weeks and emerge to the skin surface. These mites then reinfest the skin.

Modes of transmission: Transmission occurs by close skin-to-skin contact, especially in overcrowded living conditions. In adults transmission is common during sexual contact, and infestation from fomites, including infested bedding and clothing, is also possible.

Clinical features: Most patients complain of an intense pruritus especially at night and following a hot shower. The pruritus has been associated with a hypersensitivity reaction to the excreta deposited by the mite within the burrow¹⁵. The lesions are generally symmetrically distributed and usually spare the face and neck. These include small papules and vesicles, often accompanied by plaques, pustules, or nodules. The pathognomonic sign of scabies is the presence of multiple burrows on the skin typically located in the interdigital web spaces, flexural aspects of the wrist and elbows, belt line and genitals. The burrow is a fine, wavy and slightly scaly line a few millimeters to one centimeter long. A tiny mite is often visible at one end of the burrow. Although the patient may have hundreds of itching papules, often there are less than 10 burrows. Secondary lesions include papular excoriations, scaly eczematoid patches, and red-brown nodules and vesiculopustules. The burrow is often found surrounded by infiltrates of eosinophils, lymphocytes, and histiocytes on histopathology¹⁶

Diagnosis: The diagnosis of scabies is often difficult but a combination of history of pruritus especially at night, the presence of burrows on areas of predilection, and pruritus in the close family contacts are adequate for the diagnosis. The diagnosis of scabies can be rapidly confirmed by establishing the presence of mites, eggs, or scybala in the microscopic examination of scrapings of suspicious lesions¹⁷. Videodermoscopy can be utilized for primary diagnosis to detect signs of infestation (mites, eggs, and faeces), especially in children, who may refuse skin scraping.

Presentation in neonates and infants: Scabies presents differently in neonates and infants than in adults. The pathognomonic threadlike, sinuous burrows of scabies are rarely seen in neonates and infants. A history of a pruritic eruption in hospital personnel or close family members is often present¹⁸. In neonates, scabies is characterized by a large number of papulovesicular and nodular lesions, eczematization, and secondary infection, often with widespread distribution of lesions on the head, neck, scalp, palms, and soles. The affected neonates can appear irritable, feed poorly and fail to thrive. The lesions of scabies in infants constitute a variety of morphologies that produce a "flea-bitten" look. Such lesions include erythematous papules, vesicles, pustules, bullae, and crusts¹⁹.

Indiscriminate use of topical corticosteroids due to misdiagnosis of atopic dermatitis may blunt the inflammatory appearance of scabies in infants, but it does not prevent spread of the infestation. More importantly, it can also lead to the heavily crusted, hyperkeratotic lesions of Norwegian scabies that are usually seen only in immunocompromised patients¹⁹. Also, in infants there is a generalized distribution of lesions to all body areas, including the face, neck, palms,

and soles, which are not affected in adults. Again, the associated clinical symptoms include poor feeding, irritability, and failure to thrive. The possibility of scabies should be entertained for any infant who has these findings²⁰. Scabies in an infant usually means that a close adult contact is the source of the infection. The differential diagnosis for the scabies in neonates and infants, includes infantile acropustulosis, atopic dermatitis, eosinophilic pustular folliculitis, miliaria rubra, impetigo and insect bites.

Treatment and prevention: Treatment of scabies involves the control of symptoms and secondary infections, and eradication of the mites themselves. The treatment of choice for neonates, infants and young children remains topical application of 5 % permethrin lotion due to relative high safety profile and minimal absorption of the drug²¹. This is applied for 8-14 hours followed by a reapplication in one week. The entire body surface including the scalp and face should be covered for infants and young children, avoiding the areas around the eyes and mouth. The lotion should be applied from the neck down in older children and adults and should include intertrigenous and genital areas, the intergluteal cleft, and under trimmed nails. A single application is associated with an overall cure rate of 89% to 92% and could be safely used above 24 months of age safely used above 2 months of age. Less than 2% of the lotion is absorbed into the skin. Side effects include mild transient burning, stinging and erythema.

Sulfur 5-10 % in petrolatum and crotamiton 10% cream are the alternative therapies. Sulfur, which is the oldest known treatment of scabies, is the choice for infants and for pregnant or lactating women. It should be applied at night for 3 consecutive nights and washed off thoroughly 24 hours after the last application. Crotamiton cream is regarded less effective and is usually applied for five days.

Lindane 1 % cream was the treatment of choice before the introduction of permethrin, but due to concerns about its systemic and CNS toxicity (up to 10 % is absorbed), it is no longer the treatment of choice, especially in infants and young children. Moreover lindane resistant cases have been reported²². The role of oral ivermectin in the treatment of scabies remains to be determined, but it has been reported to be effective for the treatment of the severe crusted form of scabies even in severely immuno-suppressed patients in one study²³. It is mandatory to treat all the family members and close contacts even if they are not having symptoms. Bed linen and clothing should be washed in water that is at least 120°F. Dry cleaning or storage for 1 week also may be effective.

Antihistamines has to be used for a minimum period of 2 weeks. Mild-to-intermediate strength topical corticosteroids may be also used to ameliorate pruritus.

Complications, including impetigo and pustulosis due to secondary bacterial infections of excoriated scabies, should be treated with topical and/or systemic antibiotics. It is also necessary to inform the parents that the pruritus may persist for several weeks despite treatment. However, once the treatment is complete, young children can return to childcare or school.

Treatment failure is quite common and usually attributed to failure to treat all the family members and close contacts simultaneously.

Points to remember:

1. *Scabies is by far the commonest cause of itching in children in the tropics.*
2. *Scabies and pediculosis are communicable diseases.*
3. *Treatment is always aimed at a family/ community level.*

References

1. Chosidow O. Scabies and pediculosis. *Lancet* 2000;355:819-826.
2. Canyon DV, Speare R, Muller R. Spatial and kinetic factors for the transfer of head lice (*Pediculus capitis*) between hairs. *J Invest Dermatol* 2002;119:629-631.
3. Mimouni D, Ankol OE, Gdalevich M, Grotto I, Davidovitch N, Zangvil E. Seasonality trends of *Pediculosis capitis* and *Phthirus pubis* in a young adult population: follow-up of 20 years. *J Eur Acad Dermatol Venereol* 2002; 16:257-259.
4. Flinders DC, De Schweinitz P. Pediculosis and scabies. *Am Fam Physician*. 2004; 69(2):341-348.
5. Mumcuoglu KY, Friger M, Ioffe-Uspensky I, Ben-Ishai F, Miller J. Louse comb versus direct visual examination for the diagnosis of head louse infestations. *Pediatr Dermatol* 2001;18: 9-12.
6. Abramowicz M. Drugs for head lice. *Med Lett Drugs Ther* 1997;39:6-7.
7. Clore ER, Longyear LA. A comparative study of seven pediculicides and their packaged nit removal combs. *J Pediatr Health Care* 1993;17:55-60.
8. Morsy TA, Ramadan NI, Mahmoud MS, Lashen AH. On the efficacy of cotrimoxazole as an oral treatment for pediculosis capitis infestation. *J Egypt Soc Parasitol* 1996; 26: 73-77.
9. Hipolito RB, Mallorca FG, Zuniga-Macaraig ZO, Apolinario PC, Wheeler-Sherman J. Head lice infestation: single drug versus combination therapy with one percent permethrin and trimethoprim/sulfamethoxazole. *Pediatrics* 2001;107:E30.
10. Burkhart KM, Burkhart CN, Burkhart CG. Update on therapy: ivermectin is available for use against lice. *Infect Med* 1997;14:689.
11. Meinking TL, Entzel P, Villar ME, Vicaria M, Lemard GA, Porcelain SL. Comparative efficacy of treatments for pediculosis capitis infestations: update 2000. *Arch Dermatol* 2001; 137(3):287-292.
12. Magee J. Unsafe practices in the treatment of pediculosis capitis. *J School Nurs* 1996;12:17-20.
13. Elston DM. Drug-resistant lice. *Arch Dermatol*. 2003; 139(8):1061-1064
14. Morgan-Glenn PD. Scabies. *Pediatr Rev* 2001; 22(9):322-323.
15. Stricker T, Sennhauser FH. Visual diagnosis: A family that has an itchy rash. *Pediatr Rev* 2000; 21(12):428-431.
16. Leonard DD, Arrington JH 3rd. Selected problems in benign cutaneous pathology. *Pathol Ann* 1978;13:351-397.
17. Brodell RT, Helms SE. Office dermatologic testing: the scabies preparation. *Am Fam Physician*. 1991; 44(2):505-508.
18. Johr RH, Schachner LA. Neonatal dermatologic challenges. *Pediatr Rev*. 1997; 18(3):86-94.
19. Camassa F, Fania M, Ditano G, Silvestris AM, Lomuto M. Neonatal scabies. *Cutis*. 1995; 56(4):210-212.
20. Burns BR, Lampe RM, Hansen GH. Neonatal scabies. *Am J Dis Child*. 1979;133(10):1031-1034.
21. Elgart ML. Cost-benefit analysis of ivermectin, permethrin and benzyl benzoate in the management of infantile and childhood scabies. *Expert Opin Pharmacother*. 2003; 4(9):1521-1524.
22. Purvis RS, Tying SK. An outbreak of lindane-resistant scabies treated successfully with permethrin 5% cream. *J Am Acad Dermatol* 1991; 25:1015-1016.
23. del Giudice P, Marty P. Ivermectin: a new therapeutic weapon in dermatology? *Arch Dermatol* 1999; 135(6):705-706.

DERMATOLOGY

EMERGENCIES IN PEDIATRIC DERMATOLOGY

***Jayakar Thomas**

Abstract: *There are a wide range of dermatological emergencies. Intensive care is absolutely necessary in these disorders. Acute skin failure occurs secondary to several changes such as fluid loss, electrolyte imbalance, infections, etc. In fact cardiac or renal failure may be the terminal phase of acute skin failure. Toxic epidermal necrolysis have to be managed just as a case of extensive burns. Management includes careful attention to electrolyte equilibrium, nutrition, aseptic precautions, energy expenditure, and environmental temperature. All these will require time to start thinking on the lines of 'Intensive skin care units (ISCU)'.*

Key words: *Emergency, intensive skin care, acute skin failure*

The word 'emergency' means a sudden happening that needs immediate and quick attention. This event was never thought of earlier in the speciality of dermatology. But today we know that the reality is far from this and current dermatological practice has undergone tremendous change in the direction of crisp, comprehensive, and critical care being offered to various conditions ranging from urticaria through gangrenous conditions to vesiculo-bullous disorders. There are several studies on

the subject of 'emergency dermatology' in terms of the nature of consultations, either direct or referrals, in an emergency setting and in terms of evaluation of the same in tertiary care centres. Some of the common dermatological emergencies seen in the pediatric age group will be discussed and brief description of the condition and steps involved in management of the conditions are provided in this article. Novel concepts of 'acute skin failure' (ASF) similar cardiac, renal or respiratory failures and 'intensive skin care unit' (ISCU) put forward by Rene Touraine in 1976¹ will also be described briefly.

Pediatric significance

These concepts of ASF and ISCU have to be perceived with more seriousness from the pediatric point of view. The reasons for such significance in children include

- Improper development of barrier function in children
- Lack of fully formed immunological role
- Both of the above leading to increased susceptibility to infection
- Increased metabolic rates in children leading to increase in energy expenditure and this in turn demands more of fluid and nutrition supplement
- Impaired thermoregulatory function of skin in children requiring better management of ambience
- The different proportion of body weight and body surface area of a child's skin in comparison to the adult (almost three times) making it difficult to evaluate the dosage of medication to be used

* Senior Consultant Dermatologist
Kanchi Kamakoti CHILDS Trust Hospital,
Chennai and Apollo Hospitals, Chennai,
India.

- Easy haemodynamic instability resulting from increased cutaneous blood flow
- More percutaneous absorption of topical medication making the physician more alert about side effects
- All the reasons mentioned increase the chances of multi-organ and multi-system failures

Classification

For purpose of orderly thinking and for ease of presentation, the following classification of pediatric dermatological emergencies is useful.

Infections: Cellulitis, Staphylococcal scalded skin syndrome, Neonatal herpes, Neonatal candidiasis

Toxic erythemas: Urticaria and angioedema, Drug eruptions, Kawasaki syndrome

Exfoliative dermatitis

Drug reactions: Erythema multiforme, Steven Johnson Syndrome, Toxic epidermal necrolysis

Keratinization disorders: Collodion baby, Harlequin fetus

Purpuric and hemorrhagic disorders: Meningococcal disease, graft versus host disease.

Vesiculo-bullous disorders: Pemphigus, Epidermolysis bullosa, Linear IgA disease

Proliferative disorders: Hemangiomas, Histiocytosis, Mastocytosis

Miscellaneous: Acrodermatitis enteropathica, Sclerema, Leiner's disease, etc

Pediatric dermatological emergencies

A complete description of all conditions included in this group of dermatoses is not within the scope of this article and therefore only the more important ones will be discussed.

Cellulitis²

Aetiology : (i) *Streptococcus pyogenes* (group A -hemolytic streptococcus) is the most common cause of superficial cellulitis; diffuse inflammation occurs because streptokinase, DNase, and hyaluronidase-enzymes produced by the organism-break down cellular components that otherwise would contain and localize the inflammation. (ii) *Staphylococcus aureus* occasionally produces a superficial cellulitis typically less extensive than that of streptococcal origin and usually only in association with an open wound or cutaneous abscess. Superficial cellulitis caused by other organisms, primarily aerobic gram-negative bacilli, occurs rarely. With granulo-cytopenia, diabetic foot ulcers, or severe tissue ischemia, aerobic gram-negative bacilli (e.g., *Escherichia coli*, *Pseudomonas aeruginosa*) may be responsible. Unusual bacteria may cause cellulitis occurring after animal bites, especially *Pasteurella multocida* from dogs and cats. Immersion injuries in fresh water may result in cellulitis caused by *Aeromonas hydrophila*; in warm salt water, *Vibrio vulnificus* may cause cellulitis.

Clinical features

Predisposing condition : A cutaneous abnormality (e.g., skin trauma, ulceration, tinea pedis, dermatitis) often precedes the infection; areas of lymphedema or other edema seem especially susceptible. Frequently, however, no predisposing condition or site of entry is evident. Infection is most common in the lower extremities. The major findings are local erythema and tenderness, frequently with lymphangitis and regional lymphadenopathy. The skin is hot, red, and edematous, often with an infiltrated surface resembling the skin of an orange (peau d'orange). The borders are usually indistinct, except in erysipelas, a type of cellulitis in which the raised margins are sharply demarcated. Petechiae are common; large areas

of ecchymosis, rare. Vesicles and bullae may develop and rupture, occasionally with necrosis of the involved skin.

Systemic manifestations: Fever, chills, tachycardia, headache, hypotension, delirium may precede the cutaneous findings by several hours, but many patients do not appear ill. Leukocytosis is common but not constant.

Diagnosis: The diagnosis usually depends on the clinical findings. Unless pus has formed or an open wound is present, the responsible organism often is difficult to isolate, even on aspiration or skin biopsy. Blood cultures are occasionally positive. Serologic tests, especially measurement of rising titers of anti-DNase B, confirm a streptococcal cause but are usually unnecessary.

Although cellulitis and deep vein thrombosis usually are easily differentiated clinically, many physicians confuse these entities when edema occurs in the lower extremities.

Local abscesses form occasionally, requiring incision and drainage. Serious but rare complications include severe necrotizing subcutaneous infection and bacteremia with metastatic foci of infection. Even without antibiotics, most cases of superficial cellulitis resolve spontaneously; however, recurrences in the same area are common, sometimes causing serious damage to the lymphatics, chronic lymphatic obstruction, marked edema, and, rarely, elephantiasis. With antibiotics, such complications are uncommon. Symptoms and signs of superficial cellulitis usually resolve after a few days of antibiotic therapy.

Treatment: For streptococcal cellulitis, penicillin is the drug of choice. For mild outpatient cases, penicillin V 250 to 500 mg orally qid is adequate. For severe infections, which require hospitalization, aqueous penicillin G 400,000 U IV q 6 h is indicated. In penicillin-allergic patients, erythromycin 20-40 mg/kg/day

orally is effective for mild infections, and parenteral gentamicin 5 mg/kg/day for severe infections. Although *S. aureus* rarely causes typical cellulitis, many clinicians prefer using antibiotics also active against this organism: cloxacillin 25-50 mg/kg/day orally for mild infections, or cefotaxime 50-100 mg/kg/day IV for severe infections. For penicillin-allergic patients or those with suspected methicillin-resistant *S. aureus* infection, vancomycin 40 mg/kg/day in four divided doses as IV is the drug of choice. When pus or an open wound is present, results of a Gram stain should dictate antibiotic choice. Immobilization and elevation of the affected area help to reduce edema, and cool, wet dressings relieve local discomfort.

Cellulitis in a neutropenic patient requires antibiotics effective against aerobic gram-negative bacilli until culture results are available. Penicillin is the drug of choice for *P. multocida*, an aminoglycoside (e.g., gentamicin) is effective against *A. hydrophila*, and tetracycline is the preferred antibiotic for *V. vulnificus*.

Treating concomitant tinea pedis, which often eliminates the source of bacteria residing in the inflamed, macerated tissue prevents recurrent leg cellulitis. If such therapy is unsuccessful or not indicated, recurrent cellulitis sometimes can be prevented by benzathine penicillin 1.2 million U IM monthly, or penicillin V or erythromycin 250 mg orally qid for 1 week every month.

Staphylococcal Scalded Skin Syndrome³ (Ritter-Lyell Syndrome)

Staphylococcal scalded skin syndrome (SSSS) almost always occurs in infants and in children below 6 years. Epidemics may occur in nurseries, presumably transmitted by the hands of personnel in contact with an infected infant. However, nursery personnel may be nasal carriers of *S. aureus*. Sporadic cases also occur.

Aetiology: Group II coagulase-positive staphylococci, usually phage type 71 and often resistant to penicillin, elaborate exfoliatin (also called epidermolysin), an epidermolytic toxin that splits off the upper part of the epidermis just beneath the granular cell layer. The inciting infection may be on the skin but usually is in the eye or nasopharynx. The toxin enters the circulation and affects the skin systemically, as in scarlet fever.

Clinical features: In infants, illness often begins during the first few days of life with a localized crusted infection (often impetigo-like), most often at the umbilical stump or in the diaper area. Sporadic cases often start with a superficial crusted lesion, frequently around the nose or ear. Within 24 hours, tender scarlet areas appear around the crusted area and may become painful and generalized. Large, flaccid blisters arise on the erythematous skin and quickly break to produce erosions. The epidermis peels off easily, often in large sheets, when the red areas are rubbed (Nikolsky's sign). Widespread desquamation of the skin occurs within 36 to 72 hours, and patients may become very ill with systemic manifestations (e.g., malaise, chills, fever). Loss of the protective skin barrier can lead to sepsis and to fluid and electrolyte imbalance.

Symptoms and signs are indistinguishable clinically from toxic epidermal necrolysis; yet SSSS must be distinguished rapidly from TEN because therapy is different.

Diagnosis: Cultures should be obtained from the skin and nasopharynx. Diagnosis is confirmed by skin biopsy and examination of frozen tissue sections or exfoliative cytology, showing epithelial cells. Although final biopsy results may not be available until well after treatment has been started, frozen tissue sections and cytology can provide rapid confirmation.

Differential diagnosis: Drug hypersensitivity (most notably, TEN), viral exanthemas, and

scarlet fever, but none of these causes a painful rash. Bullae, erosions, and an easily loosened epidermis occur in thermal burns, genetic bullous diseases (e.g., some types of epidermolysis bullosa), and acquired bullous diseases (e.g., pemphigus vulgaris, bullous pemphigoid).

Treatment: With prompt diagnosis and therapy, death rarely occurs. Systemic penicillinase-resistant antistaphylococcal antibiotics (e.g., cloxacillin) must be started as soon as the clinical diagnosis is made, without waiting for culture results. In early-stage disease, oral cloxacillin 12.5 mg/kg q 6 h (for infants and children weighing ≤ 20 kg) and 250 to 500 mg q 6 h (for older children) may be given; in severe disease, gentamicin IV in 2 divided doses should be additionally given until improvement is noted, followed by oral cloxacillin 25 mg/kg/day up to 100 mg/kg/day for more than 10 days. Corticosteroids are contraindicated, and topical therapy and patient handling must be minimized. If the disease is widespread and the lesions are weeping, the skin should be treated as if it were burned. Hydrolyzed polymer gel dressings may be very useful, and the number of dressing changes should be minimized. Because the split is high in the epidermis, the stratum corneum is quickly replaced and healing is usually within 5 to 7 days after the start of treatment. Steps to detect carriers and prevent or treat nursery epidemics are to be taken.

Neonatal herpes simplex virus infection ⁴

Epidemiology: Infection with herpes simplex virus by transmission during parturition, typically causing vesicular eruption and subsequent disseminated disease. Neonatal herpes simplex virus (HSV) infection has high mortality and significant morbidity. Incidence estimates range from 1/3,000 to 1/20,000 live births. HSV type 2 occurs in about 80% of cases; 20% are caused by HSV type 1. HSV type 2 is usually transmitted to the newborn during delivery by passage

through an infected maternal genital tract. Transplacental transmission of virus and nosocomial spread from one newborn to another by hospital personnel or family has also been implicated in about 15% of cases. Mothers of newborns with HSV infection tend to have no history or symptoms of genital infection at the time of delivery.

Clinical features: Manifestations generally occur between the first and second week of life; however, symptoms may not appear until as late as the fourth week. The hallmark of infection is skin vesicles, which, if untreated, frequently leads to progressive or more serious forms of disease within 7 to 10 days. However, up to 45% of infected newborns initially have no skin vesicles; usually these newborns have localized CNS disease. Other signs of infection, which can occur singly or in combination, include temperature instability, lethargy, hypotonia, respiratory difficulty (apnea or pneumonia), convulsions, hepatitis, and disseminated intravascular coagulation (DIC).

Newborns with disseminated disease and visceral organ involvement have hepatitis, pneumonitis, and/or DIC with or without encephalitis or skin disease.

Newborns with localized disease can be subdivided into two groups. The first group has encephalitis manifested by neurologic findings, CSF pleocytosis, and elevated protein concentration, with or without concomitant involvement of the skin, eyes, and mouth. The second group has only skin, eye, and mouth involvement and no evidence of CNS or organ disease.

Diagnosis: Rapid and specific diagnosis of neonatal HSV infection is essential. Infection can be confirmed by isolating virus in tissue culture, using various cell lines of human or nonhuman origin. The most common site of retrieval is a

skin vesicle; the mouth, eye, and CSF are also high-yield sites. In some newborns presenting with encephalitis, virus is found only in the brain; however, accurate testing (such as HSV polymerase chain reaction) is available in only a few research and specialized laboratories. Cytopathologic effects usually can be demonstrated in tissue culture within 24 to 48 hours after inoculation. The diagnosis can also be confirmed by neutralization with appropriate high-titer antiserum; immunofluorescence of lesion scrapings, particularly with use of monoclonal antibodies; and electron microscopy. If no diagnostic virology facilities are available, a Leishman smear of the lesion base may show characteristic histopathologic evidence (multinucleated giant cells and intranuclear inclusions), but this is less sensitive than culture, and false-positive results occur.

In newborns with untreated disseminated disease, mortality rate is 50%, while in untreated local disease and encephalitis it is 50%. At least 95% of the survivors have severe neurologic sequelae. Death is uncommon in those with local (skin, eyes, mouth) disease but without CNS or organ disease, except as the result of concomitant medical problems. About 30% develop neurologic impairment, which may not manifest until 2 to 3 years of age. Morbidity in each group parallels mortality and is directly proportional to disease extent. About 90% of infants with visceraally disseminated neonatal HSV infection have subsequent sequelae. Only 5% of those with CNS infection return to normal. Therapy with acyclovir not only decreases the mortality rate by 50% but also increases the percentage who recovers completely from 10 to 50%.

Treatment: Acyclovir 30 mg/kg/day as infusion with normal saline is given in 3 divided doses for 10 to 14 days. Vigorous supportive therapy is required, including appropriate IV fluids, alimentation, respiratory support, correction of

clotting abnormalities, and control of seizures. Herpes keratoconjunctivitis requires concomitant systemic acyclovir and topical therapy with a drug such as trifluridine.

Neonatal candidiasis⁵

Systemic or cutaneous candidiasis presenting within 12 hours of birth is classified as congenital candidial infection. It is an intrauterine infection acquired by ascending or cervical infection. Oral mucosa and diaper areas are not involved. The presentation is initially as a morbiliform eruption, erythematous macules, papulo-vesicles, or pustules. The condition is best treated with ketoconazole in a dosage of 3mg / kg /day for 7 to 10 days.

Drug eruptions⁶ (Dermatitis medicamentosa)

Although the mechanisms of most drug eruptions are unknown, many are allergic. Specific antibodies or sensitized lymphocytes to the drug may develop as soon as 4 or 5 days after initial drug exposure. A later eruption caused by re-exposure to the drug may appear within minutes but may be delayed for days or longer. Other reactions may be caused by accumulation of a drug (e.g., pigmentation from silver), pharmacologic action of a drug (e.g., striae or acne from systemic corticosteroids, purpura from excessive anticoagulation), or interaction with genetic factors (e.g., porphyria cutanea tarda from estrogens, which induce an enzyme involved in porphyrin metabolism).

Drug eruptions vary from a mild rash to toxic epidermal necrolysis. Onset may be sudden (e.g., urticaria or angioedema from penicillin) or delayed for hours or days (morbilliform or maculopapular eruptions from penicillin or sulfonamides) or for years (exfoliation or pigmentation from arsenic). The lesions may be localized (fixed drug eruptions, oral ulcers, dermatitis in light-exposed areas), but many are

generalized. Reactions may be characteristic of certain drugs or may imitate features of practically any dermatosis. The drugs added to therapy most recently are most likely to be the cause, but drugs taken for long periods must also be suspected.

Identification of the causative agent is essential. A detailed history is often required, with persistent inquiry about all drugs, including (over the counter) drugs for sleep, pain, colds, constipation, and headache and eye drops, nasal drops, and suppositories. Some eruptions start after the drug has been stopped (e.g., ampicillin) and continue for weeks or months; minute amounts of some drugs may produce a reaction. However, most drug reactions resolve when the offending drug is stopped and require no further therapy. Often, especially in hospitalized patients, all but life-sustaining drugs can be discontinued and each reinstituted at weekly intervals in order of importance. A physician well versed in the incidence and types of drug eruptions can often withhold the most likely offender while continuing all other drugs. When suspected offending drugs are essential, chemically unrelated compounds should be substituted when possible. No laboratory tests are available to aid diagnosis, although lymphocyte transformation and penicillin skin tests are under study. Biopsy of affected skin may be helpful. Sensitivity can be definitively established only by readministration of the drug, but this may be hazardous or unethical.

A lubricant (e.g., white petrolatum) may provide symptomatic relief for a dry, itching maculopapular eruption. A fluorinated corticosteroid ointment may be applied in a small area initially and, if effective, applied to the entire eruption. Acute urticaria may be a sign of anaphylaxis and may require aqueous epinephrine (1:1000) 0.2 ml sc or IM or the slower-acting but more persistent soluble

hydrocortisone 100 mg IV, which may be followed by an oral corticosteroid for a short period.

Kawasaki syndrome⁷

A syndrome occurring usually in infants and children less than 5 years, characterized by prolonged fever, exanthem, conjunctivitis, mucous membrane inflammation, cervical lymphadenopathy, and polyarteritis of variable severity. Though its etiology is unknown, the epidemiology and clinical presentation suggest an infection or an abnormal immunologic response to an infection.

Since the syndrome was first described in Japan in the late 1960s, thousands of cases have been reported worldwide in diverse racial and ethnic groups, although children of Japanese descent have a higher incidence. The male:female ratio is about 1.5:1. Eighty percent of patients are less than 5 years (median, 2 years); true cases in teenagers or adults are rare. Cases occur year-round, but most often in spring or winter. Clusters have been reported in communities without clear evidence of person-to-person spread. Recurrences occur in about 1% of patients.

The pathology is nearly identical to infantile polyarteritis nodosa, with vasculitis primarily affecting the coronary arteries but also other medium-sized and large arteries.

The illness tends to progress in stages, beginning with fever, usually remittent and $>39^{\circ}\text{C}$ ($>102.2^{\circ}\text{F}$), which is associated with irritability, often extreme, and occasional lethargy or intermittent colicky abdominal pain. Fever lasts 1 to 2 weeks or more in untreated patients. Usually within a day or two of fever onset, bilateral bulbar conjunctival injection without exudate appears. Within 5 days, a polymorphous, erythematous macular rash appears, primarily

over the trunk, often with accentuation in the perineal region. The rash may be urticarial, morbilliform, or scarlatiniform and is accompanied by injected pharynx; reddened, dry, fissured lips; and a red strawberry tongue. During the first week, pallor of the proximal portion of the fingernails or toenails (leukonychia partialis) may occur. Erythema or a purple-red discoloration and variable edema of the palms and soles usually appear on about the third to fifth day. Although edema may be slight, it is often tense, hard, and nonpitting. Periungual, palmar, and plantar desquamation begins on about the tenth day after onset. The superficial layer of the skin sometimes comes off in large casts, revealing new normal skin. Tender, nonsuppurative cervical lymphadenopathy (≥ 1 node ≥ 1.5 cm in size) is present throughout the course in about 50% of patients; the other findings each are present in about 90% of patients. The illness may last from 2 to 12 weeks or longer. Other less specific findings indicate involvement of many systems. Arthritis or arthralgias (mainly involving large joints) occur in about 1/3 of patients. Other clinical features may include urethritis, aseptic meningitis, diarrhea, hydrops of the gallbladder, and anterior uveitis.

The most important complications are those of cardiac inflammation, most notably coronary arteritis. Cardiac manifestations usually begin on about the tenth day, as the rash, fever, and other early acute clinical symptoms begin to subside; i.e., in a subacute phase of the syndrome. Inflammation of the coronary arteries with dilation and aneurysm formation occurs in 5 to 20% of all cases, sometimes associated with acute myocarditis with heart failure, arrhythmias, and pericarditis, and rarely with cardiac tamponade, thrombosis, or infarction.

Diagnosis is based on the clinical findings and on exclusion of other diseases. Results of

cultures for bacteria and viruses, as well as serologic tests for evidence of infection, are negative but may be useful for diagnosing other illnesses with similar presentations.

Differential diagnosis includes bacterial diseases (especially scarlet fever, staphylococcal exfoliative syndromes, and leptospirosis), viral exanthems (e.g., measles, viral hemorrhagic fever), toxoplasmosis, acrodynia (caused by mercury poisoning), Stevens-Johnson syndrome, and juvenile RA.

Children with Kawasaki syndrome should be treated by or in close consultation with an experienced pediatric cardiologist or pediatric infectious disease specialist. Therapy is started as soon as possible, optimally within the first 10 days of illness, with a combination of high-dose intravenous immunoglobulin (IVIG—a single dose of 2 g/kg given over 10 to 12 h) and oral high-dose aspirin (80 to 100 mg/kg/day in 4 divided doses). The aspirin dose is reduced to 3 to 5 mg/kg/day as a single dose when the child becomes afebrile.

A small risk of Reye's syndrome exists in children receiving long-term aspirin during outbreaks of influenza or varicella. Parents of children receiving aspirin should be instructed to contact the physician promptly if the child is exposed to or develops symptoms of influenza or varicella. Temporary interruption of aspirin may be considered (with substitution of dipyridamole for children with documented aneurysms). Annual influenza vaccination is indicated for children receiving long-term aspirin therapy.

Generalized exfoliative dermatitis ⁸

Usually no cause is found. Some cases are secondary to certain dermatitides (e.g., atopic, psoriatic, pityriasis rubra pilaris, contact dermatitis); others may be induced by a systemic

drug (e.g., penicillin, sulfonamides, isoniazid, phenytoin, barbiturates) or a topical agent. Exfoliative dermatitis may also be associated with mycosis fungoides or lymphoma.

The onset may be insidious or rapid. The entire skin surface becomes red, scaly, thickened, and occasionally crusted. Pruritus may be severe or absent. The characteristic appearance of any primary dermatitis is usually lost. Localized areas of normal skin may be seen when the exfoliative dermatitis is caused by such conditions as psoriasis, mycosis fungoides, or pityriasis rubra pilaris. Generalized superficial lymphadenopathy is frequent, but biopsy usually shows benign lymphadenitis.

The child may feel cold and have an elevated temperature caused by excessive heat loss from increased blood flow to the skin. Generalized exfoliative dermatitis may also cause weight loss, hypoproteinemia, hypocalcaemia, iron deficiency, or (in patients with borderline cardiac compensation) high-output heart failure.

Every attempt must be made to determine the cause. A history or signs of a primary dermatitis may be helpful. Biopsy is usually not helpful, but pemphigus foliaceus or mycosis fungoides may be diagnosed by skin biopsy, or lymphoma by a lymph node biopsy. Sézary syndrome may be diagnosed by a blood smear.

The disease may be life-threatening, and hospitalization is often necessary. Because drug eruptions and contact dermatitis cannot be ruled out by history alone, all drugs should be stopped, if possible, or essential systemic drugs should be changed to chemically dissimilar ones. Petrolatum applied after tap-water baths gives temporary relief. Oral corticosteroids should be used only when other measures fail. Prednisolone 40 to 60 mg/day is given; after about 10 days, the drug is given on alternate days. Usually the dose can be further decreased, but if an

underlying cause is not eliminated, long-term prednisolone will be required.

Erythema multiforme ⁹

An inflammatory eruption characterized by symmetric erythematous, edematous, or bullous lesions of the skin or mucous membranes.

No cause of erythema multiforme can be found in over 50% of cases. Most other cases are due to infectious diseases (e.g., herpes simplex [probably most common], coxsackie and echo viruses, *Mycoplasma pneumoniae*, psittacosis, histoplasmosis) or drug therapy. Almost any drug can cause erythema multiforme; penicillin, sulfonamides, and barbiturates are the most likely. Vaccinia, Bacille Calmette-Guérin (BCG), and poliomyelitis vaccines have also induced erythema multiforme.

The mechanism by which infectious agents, drugs, or vaccines cause erythema multiforme is unknown, but it is generally considered a hypersensitivity reaction.

Onset is usually sudden, with erythematous macules, papules, wheals, vesicles, and sometimes bullae appearing mainly on the distal portion of the extremities (palms, soles) and on the face; hemorrhagic lesions of the lips and oral mucosa can also occur. The skin lesions (target or iris lesions) are symmetric in distribution and often annular, with concentric rings, central purpura, and greyish discoloration of the epidermis or vesicle. Itching is variable. Systemic symptoms vary; malaise, arthralgia, and fever are frequent. Attacks sometimes last 2 to 4 weeks and recur in the fall and spring for several years.

Stevens-Johnson syndrome is a severe form of erythema multiforme (erythema multiforme major) characterized by bullae on the oral mucosa, pharynx, anogenital region, and conjunctiva; target-like lesions; and fever. The patient may be unable to eat or properly close

the mouth. The eyes may become very painful; purulent conjunctivitis may make it impossible for the patient to open them. Symblepharon production, keratitis with corneal ulceration, iritis, and uveitis may occur. The conjunctival lesions may leave resistant corneal opacity and synechia. The condition is occasionally fatal.

The skin lesions of erythema multiforme must be distinguished from bullous pemphigoid, urticaria, and dermatitis herpetiformis; the oral lesions, from aphthous stomatitis, pemphigus, and herpetic stomatitis. Hand, foot, and mouth disease produced by coxsackieviruses A5, A10, and A16 must also be considered. Pneumonia should be treated with tetracycline. Local treatment depends on the type of lesion. Vesicles and bullous or erosive lesions can be treated with intermittent Burrow's solution, saline, or tap-water compresses. Cheilitis and stomatitis of erythema multiforme require special care. Use of systemic corticosteroids is controversial; some patients, especially those with severe mouth and throat lesions, seem to succumb more readily to fatal respiratory complications. The cause, if found, should be treated, eliminated, or avoided. Simple erythema often needs no treatment. Systemic antibiotics (as indicated by culture and sensitivity) and fluid and electrolyte replacement may be lifesaving in children with extensive mucous membrane lesions. If frequent or severe erythema multiforme is preceded by herpes simplex, acyclovir 200 mg orally five times daily may prevent attacks.

Toxic epidermal necrolysis ¹⁰

Toxic epidermal necrolysis (TEN) more often occurs in adults. Sulfonamides, barbiturates, NSAIDs, phenytoin, allopurinol, and penicillin are most frequently associated, but numerous other drugs have been less commonly implicated. Intake of drugs is denied by about 1/5 of patients. In about 1/3 of cases, the cause is unclear because of concomitant serious disease

and drug treatment. TEN is one of the few true dermatologic emergencies and mortality rate is 61%.

TEN typically begins with painful localized erythema that disseminates rapidly. At the sites of erythema, flaccid blisters occur or the epidermis peels off in large sheets with gentle touching or pulling (Nikolsky's sign). Malaise, chills, myalgias, and fever accompany the denudation. Widespread areas of erosion, including all mucous membranes (eyes, mouth, genitalia), occur within 24 to 72 hours, and the patient may become gravely ill. Affected areas of skin often resemble second-degree burns. Death is caused by fluid and electrolyte imbalance and multiorgan sequelae (e.g., pneumonia, GI bleeding, glomerulonephritis, hepatitis, infection). Rapid diagnosis is important so that a possibly offending drug can be stopped. Before widespread erythema and epidermal denudation occur, it may be difficult to distinguish TEN from morbilliform drug eruptions or erythema multiforme minor and the Stevens-Johnson syndrome (erythema multiforme major). TEN is often thought to be a continuum of the latter two diseases. Although

TEN closely resembles staphylococcal scalded skin syndrome, these disorders can be differentiated by the patient's age, the clinical setting, and the level of the epidermal split seen on biopsy (Table 3).

Patients should be hospitalized; excellent nursing care and close observation are essential. Suspected drugs should be stopped immediately. Patients should be isolated to minimize exogenous infection and treated as are those with severe burns by protecting the skin and denuded areas from trauma and infection and by replacing fluid and electrolyte losses.

Although controversial, systemic corticosteroid use has been successful when initiated early in the course of disease. The idea is to stop further immunologic injury to the skin, but systemic corticosteroids will not breathe life into dead keratinocytes or reverse programmed death of skin. Some severe cases require high-dose parenteral corticosteroids for several days. This type of corticosteroid therapy has been associated with many adverse effects and should be given under well-controlled conditions. Corticosteroids often seem to enhance the propensity to gram-negative or other sepsis and

Table 1. Differentiating features between SSSS, SJS and TEN

| Character | Staphylococcal scalded skin syndrome | Stevens johnson syndrome | Toxic epidermal necrolysis |
|---------------------|--------------------------------------|--------------------------|---------------------------------|
| Presentation | Ill child | Very ill child | Very ill child |
| Clinical | Vesicles, bullae, pustules | Bullae, Target lesions | Denuded skin |
| Mucosal involvement | No | Yes | No |
| History | Infection throat, eye, vagina | Infections, drugs | Drugs |
| Body surface area | NA | 10% | >30% |
| Usual sites | Around orifices | In and around orifices | All over |
| Biopsy | Subcorneal sub epidermal | Intra epidermal and | Subcorneal |
| Cytology | Not contributory | Inflammatory cells | Epithelial cells |
| Treatment | Antibiotics | Antibiotics and steroids | Antibiotics, steroids and IV GG |

increase the mortality rate; thus, if these drugs are used, a short course is safer. Septicemia, the most common cause of death, often occurs with pulmonary infections and must be recognized and treated promptly. Ophthalmologic consultation is often required because there may be considerable crusting of the conjunctiva. To prevent phimosis, urologic consultation may be necessary.

Collodion baby ¹¹

Autosomal recessive lamellar ichthyosis manifest as collodion babies. These babies are born with a thick armour-like collodion membrane around them that is replaced much later by essentially normal skin. Such babies are at a high risk of dehydration, sepsis, and temperature lability. Emollients such as liquid paraffin are the best topical agents helpful along with control of infection. Topical salicylic acid should never be used because of the danger of salicylism and likewise topical steroids are to be avoided to prevent rapidly developing adrenal suppression.

Meningococcal disease ¹²

Meningococcal disease is an illness caused by the bacteria *Neisseria meningitidis*. The two common presentations of meningococcal infection are meningococcal meningitis and meningo-cocemia. An infected individual may suffer one or both of these diseases.

Meningococcal disease is a medical emergency and patients showing signs and symptoms suspicious of meningococcal infection need to seek medical advice from their doctor or a hospital immediately. A delay of even hours can be fatal.

Most patients with meningococcal disease are otherwise healthy individuals. However, there are some patient groups who are at an increased risk for developing meningococcal infection.

- Children 6 months to 4 years – until about 6 months immunity from the mother is present. Beyond 4 years many children have developed immunity to many strains of *Neisseria meningitidis*.
- Individuals with complement deficiencies. Complement is a part of the immune system required for the breakdown of meningococcal bacteria.
- Individuals without spleen (asplenic).
- Individuals taking immunosuppressive drugs such as prednisolone or cyclosporin.
- Individuals with a current viral infection.

The most common signs and symptoms of meningococcal disease are listed in the Table 2.

If an individual has both meningococcal meningitis and meningococemia, they may present with a mixture of symptoms and signs characteristic to each of the diseases.

Meningococcal meningitis and meningococemia is often suspected from the history and physical examination. Blood culture and/or lumbar puncture are used to confirm diagnosis. An increased number of white cells are seen under the microscope

Early recognition of meningococcal infection is critical as meningococemia spreads so quickly that within hours of symptoms of appearance, a patient may rapidly deteriorate and die. Patients may initially just have a rash and not be particularly unwell. Meningococemia can kill more rapidly than any other infectious disease. Patients with either meningococemia or meningococcal meningitis must be hospitalized and treatment with antibiotics and supportive care instituted immediately. Many patients are admitted to an intensive care unit.

Penicillin is the drug of choice. Some strains of *Neisseria meningitidis* are resistant to penicillin

Table 2. Symptoms and signs of meningococcal disease

| | |
|--|--|
| Meningococcal meningitis Children >1 year and adults <ul style="list-style-type: none"> • Neck stiffness • Headache • Nausea and vomiting • Neck and/or back pain • Fever and chills • Increased sensitivity to light • Irritability, confusion | Meningococemia Signs on the skin <ul style="list-style-type: none"> • Petechiae (rash of small red or purple spots that do not disappear when pressure is applied to the skin) occur in 50-75% of cases. • Rash may progress to larger red patches or purple lesions (similar to bruises). • Most often found on the trunk and extremities but may progress to involve any part of the body. • In severe cases lesions may burst and lead to necrosis. |
| Infants <ul style="list-style-type: none"> • Refusing feeds • Increased irritability • Sleeping all the time • Fever • Bulging fontanelle (soft spot on the top of the head) • Inconsolable crying • Epileptic fits (seizures) | Other signs and symptoms <ul style="list-style-type: none"> • Acute fever and chills • Headache • Neck stiffness • Low back and thigh pain • Nausea and vomiting • Confusion or unconsciousness • Epileptic fits (seizures) • Unstable vital signs, e.g. very low blood pressure, reduced blood flow, low urine output • Collapse from septic shock |

have been isolated; in these cases, third-generation cephalosporins are a suitable alternative. Very sick patients are often treated with both penicillin and cephalosporins prior to obtaining the laboratory results.

Other treatments may include:

- intravenous fluids to treat shock and prevent organ damage
- medications such as noradrenaline for patients with very low blood pressure
- blood products such as platelets and fresh frozen plasma
- oxygen and mechanical ventilation as needed

Patients who survive very severe cases of meningococemia may have suffered severe necrosis of skin and underlying tissue. Skin grafts and amputation may be necessary.

Complications from meningococcal disease may occur at the time of the acute disease or during the recovery period. Some complications are so severe that they may reduce the chances of survival.

- Massive hemorrhage of the adrenal glands
- Disseminated intravascular coagulopathy (DIC), which prevents blood clotting
- Arthritis
- Heart problems, e.g. pericarditis (inflammation of the sack surrounding the heart)
- Neurological problems, e.g. deafness or peripheral neuropathy (damage to the nerves in feet and hands)
- Permanent musculoskeletal problems
- Amputation

Graft versus host disease¹³

Graft versus host disease (GVHD) is a condition where following transplantation the donor's immune cells in the transplant (graft) make antibodies against the patient's tissues (host) and attack vital organs. Organs most often affected include the skin, gastrointestinal (GI) tract and the liver.

Ninety percent of bone marrow transplants lead to GVHD. Solid organ transplantation, blood transfusions, and maternal-fetal transfusions have also been reported to cause GVHD less frequently.

There are two forms of GVHD.

- Acute GVHD
 - Early form of GVHD that occurs within the first 3 months of transplantation
 - First sign is usually a skin rash appearing on the hands, feet and face
 - Gastrointestinal and liver dysfunction symptoms may follow

- Chronic GVHD

- Late form of GVHD that develops 3 months post transplantation
- Usually evolves from acute GVHD but occurs de novo in 20-30% of patients
- Cutaneous (skin) reactions resemble those of autoimmune disorders such as lupus, lichen planus and especially systemic sclerosis

Acute GVHD and chronic GVHD are distinct diseases. One common factor is that they both increase the patient's susceptibility to infection (Table 3).

Patients recovering from bone marrow transplantation are usually hospitalized for several weeks following transplant and are monitored closely for signs of developing GVHD or infection. The best treatment for GVHD is prevention. This consists of a cocktail of immunosuppressive drugs such as cyclosporin, methotrexate, cyclophosphamide, mycophenolate, tacrolimus and sirolimus, with

Table 3. Features of acute and chronic GVHD

| Acute GVHD | Chronic GVHD |
|--|--|
| <ul style="list-style-type: none"> · Tender, red spots usually appear 10-30 days post transplantation · Face, hands and feet affected first then spreading to whole body (erythroderma) · Spots may coalesce to form widespread red rash · Rash may develop into raised spots or blisters that resemble toxic epidermal necrolysis · Fever may be present · Watery or bloody diarrhea with stomach cramps indicates GI involvement · Jaundice (yellowing of the skin and eyes) indicates liver involvement · Abnormal liver function tests | <ul style="list-style-type: none"> · Dry, itchy raised rash develops over whole body · Dry mouth and sensitivity to spicy or acid foods leading to mouth lesions · Dry eyes causing irritation and redness · Skin thickening, scaling, hyper- or hypopigmentation (resembling lichen planus) · Hardening of skin (scleroderma) may interfere with joint mobility · Hair loss or premature graying · Decreased sweating · Liver involvement causing jaundice · Lung and GI disorders may occur |

or without prednisolone. The combination of cyclosporin and methotrexate has been found to significantly decrease the severity of GVHD. These drugs weaken the ability of the donor's immune cells to launch an attack on the patient's organs.

Treatment for patients who do develop GVHD depends on the severity of the disease. Mild cases with only skin involvement of acute GVHD may settle without treatment. More severe acute or chronic GVHD predisposes the patient to infection and overwhelming sepsis is the main cause of death in patients with GVHD. The aim is to treat GVHD before life-threatening sepsis occurs. High dose corticosteroids are usually added to the immunosuppressive regime. New monoclonal antibodies appear very effective but are very costly. Photochemotherapy (PUVA) and high dose long wave ultraviolet radiation (UVR) may reduce the severity of the skin problems.

Epidermolysis bullosa¹⁴

Several forms are described of this disease, but only the major life-threatening forms are discussed here (Table 4 & 5).

There is no cure for EB. Treatment is symptomatic and the primary aim is to protect the skin and stop blister formation, promote healing and prevent complications. Because EB can affect so many different parts of the body, a team of medical specialists is usually required for overall care. When necessary, treatment with oral and topical medications may be prescribed to assist healing or prevent complications.

The following are some general measures used in caring for a patient with EB.

- Maintain a cool environment and avoid overheating
- Use foam padding or sheepskins to help reduce friction on furniture such as beds, chairs and infant car seats

- Wear clothing made of soft non-irritating fabrics
- Pierce, drain and dress blisters to promote healing (this should be done only by people who have received training on wound care)
- Try to avoid using nappies in infants with severe EB, instead place child on a clean pad

Linear IgA Disease¹⁵

Linear IgA disease is a rare blistering disorder. It is nearly identical to a similar condition that affects children, chronic bullous disease of childhood.

Chronic bullous disease of childhood usually presents before puberty with an abrupt onset of blistering in the genital region, later affecting hands, feet and face. In adults with linear IgA disease, the limbs are more often the first sites, although any area of the body may be affected later.

Clear round or oval blisters may arise from normal-looking or red skin. Red flat or elevated patches may arise, studded with small blisters (vesicles) or large ones (bullae), often target-shaped. The tendency for new blisters to arise in a ring around an old one is called the string of beads sign, and groups of small blisters may be described as a cluster of jewels. Crusts, scratch-marks, sores and ulcers may arise. The lesions can resemble other uncommon blistering skin diseases especially erythema multiforme, bullous pemphigoid and dermatitis herpetiformis. The intensity of itching is variable. Blisters and ulceration on the lips and inside the mouth affect about 50%. Eye involvement may result in irritation, dryness, light sensitivity, and blurred vision. Biopsy shows a subepidermal blister. Direct immunofluorescence, reveals the immunoglobulin IgA along the basement membrane of the epidermis in a linear pattern. Sometimes these IgA antibodies can be detected

Table 4. Junctional epidermolysis bullosa (JEB)

| JEB Subtypes | Features |
|-------------------------------------|--|
| Herlitz (JEB letalis or lethal JEB) | <ul style="list-style-type: none"> · Generalized and most severe form of JEB where blisters appear all over the body and often involve mucous membranes and internal organs · May only present at birth with small single blister but becoming more widespread soon after · Hoarse cry or cough is indicative of internal organ involvement · Complications such as infection, malnutrition and dehydration usually lead to early death in infancy |
| JEB mitis or non-lethal JEB | <ul style="list-style-type: none"> · Generalized blistering and mucosal involvement present at birth or soon after · Scalp, nails and tooth more involved · Complications such as infection, malnutrition and dehydration may cause death in infancy but those who survive clinically improve with increasing age |
| Generalized atrophic benign EB | <ul style="list-style-type: none"> · Mild generalized blistering present at birth, usually with scalp, nail and teeth involvement · Blisters heal with a distinctive atrophic appearance · Blisters worsen in warmer climates |

Table 5. Dystrophic epidermolysis bullosa (DEB)

| DEB Subtypes | Features |
|---------------------|--|
| Dominant DEB | <ul style="list-style-type: none"> · Generalized blistering present at birth · Blistering becomes localized to hands, feet, elbow or knees as child grows older and in response to friction · Small white spots called milia are often present at healed but scarred sites |
| Recessive DEB | <ul style="list-style-type: none"> · May be mild or severe presentations · Generalized severe blistering is more common and involves large areas of skin and mucous membranes · Blisters heal but with scarring and deformity causing limited movement as fingers and toes may be fused together · Complications such as infection, malnutrition and dehydration may cause death in infancy and those that survive are at great risk of developing squamous cell carcinoma |

in the blood (indirect immunofluorescence). Research indicates the antibodies are directed against various basement membrane components (target antigens).

Most children with Linear IgA disease improve or clear with Dapsone 50–100mg daily. Other helpful medications include: Corticosteroids (prednisolone) and erythromycin. Although the condition may eventually be cured, many patients require long-term treatment as a reduction in dose of medication results in further blistering.

Hemangiomas ¹⁶

These vascular proliferations or ectasias are grouped as superficial, deep, and mixed. Infants are at a great risk during the first 6 months of age. However the danger is governed by factors such as site and size of the angioma. Vascular malformations have to be distinguished from hemangiomas. A vascular malformation is almost always present from birth, remains stable or might progress very slowly. The absence of brisk proliferative response in vascular malformations is due to the absence of endothelial cell proliferation. Unlike hemangiomas, they do not resolve spontaneously. Hemangiomas will need early treatment when interference with vital functions expected can occur (like around the eye, nose, ear, throat) or with Kasabach-Merritt syndrome or congestive heart failure. When treatment is required, oral prednisolone 1 to 3 mg/kg bid or tid should be given as soon as possible and for about 2 weeks. If resolution starts, the prednisolone should be decreased slowly; if not, the drug should be stopped. Interferon alfa is an antiangiogenic drug that inhibits epithelial cell proliferation and motility and is the first line of therapy in Kasabach-Merritt syndrome.

Histiocytosis X ¹⁷

Langerhans' cell granulomatosis

(histiocytosis X) is a group of disorders (Letterer-Siwe disease, Hand-Schüller-Christian disease, pulmonary histiocytosis X) in which histiocytes and eosinophils proliferate, especially in the skin, bone and lung, often causing scarring. The cause of these disorders is not known. They all start with infiltration of the lung (and other tissues) by histiocytes, which are cells that scavenge for foreign materials, and to a lesser extent by eosinophils, which are cells that are normally involved in allergic reactions.

Letterer-Siwe disease starts before age 3 and is usually fatal without treatment. The histiocytes damage not only the lungs but also the skin, lymph glands, bones, liver, and spleen. A small portion of the lung may rupture into the pleural space (pneumothorax). Hand-Schüller-Christian disease usually begins in early childhood but can start in late middle age. The lungs and bones are most frequently affected. Rarely, damage to the pituitary gland causes diabetes insipidus, a condition in which large quantities of urine are produced, leading to dehydration. Some people develop bulging eyes (exophthalmos) because the bones of the eye sockets are affected. Pulmonary histiocytosis X (eosinophilic granuloma) is a rare, smoking-related lung disease. The disease occurs more often in men than in women. Symptoms usually start between the ages of 20 and 40. About 16% of people have no symptoms, but the rest develop coughing, shortness of breath, fever, chest pain, and weight loss. Pneumothorax is a common complication due to rupture of a lung cyst. Scarring makes the lungs stiff and impairs their ability to transfer oxygen into and out of the blood.

Chest x-rays show nodules, small lung cysts (honeycombing), and other changes that are typical of these diseases. X-rays may also show that the bones are affected. Pulmonary function tests show reduced function. Coughing up of blood (hemoptysis) and diabetes insipidus are rare complications.

People with Hand-Schüller-Christian disease may recover spontaneously. Most people with pulmonary histiocytosis X have persistent or progressive disease. Death usually results from respiratory failure or cor pulmonale, although when people with pulmonary histiocytosis X stop smoking, improvement occurs in about one third of cases. All three disorders may be treated with corticosteroids and immunosuppressant drugs such as cyclophosphamide, although no therapy is clearly beneficial. The treatment for affected bones is similar to that for bone tumors.

Mastocytosis¹⁸

A condition of unknown etiology characterized by excessive accumulation of mast cells in various body organs and tissues. Tissue mast cells may contribute to host defense by releasing potent preformed mediators (e.g., histamine) from their granules and by generating newly formed mediators (e.g., leukotrienes) from membrane lipids. Normal tissue mast cells also mediate the symptoms of common allergic reactions by means of IgE antibodies attached to specific surface receptors. Mastocytosis can occur in three forms: mastocytoma (a benign cutaneous tumor); urticaria pigmentosa (multiple small cutaneous collections of mast cells that develop as salmon-colored or brown macules and papules, which urticate when stroked and may become vesicular or even bullous); and systemic mastocytosis (mast cell infiltrates in the skin, lymph nodes, liver, spleen, GI tract, and bones).

Patients with systemic mastocytosis have arthralgias, bone pain, and anaphylactoid symptoms. Other symptoms (increased gastric acid and mucus secretion) are caused by stimulation of H₂ receptors. Thus, peptic ulcer disease and chronic diarrhea are common problems. The histamine content of tissue biopsies can be extremely high, commensurate with the elevated mast cell concentration. The urinary excretion of histamine and metabolites

is high in systemic mastocytosis, and plasma histamine may be elevated. Increased plasma levels of tryptase, heparin, and prostaglandin D₂ have also been reported.

Cutaneous disease involutes spontaneously; urticaria pigmentosa either clears completely or is substantially improved before adolescence. These conditions rarely progress to systemic mastocytosis. Usually, only treatment of pruritus with an H₁ blocker is needed. The symptoms of systemic mastocytosis should be treated with an H₁ and an H₂ blocker. Because prostaglandins, especially prostaglandin D₂, may contribute to mast cell-related symptoms, aspirin therapy may be tried cautiously; while inhibiting prostaglandin synthesis, aspirin and similar drugs may enhance leukotriene production. If GI symptoms are not controlled, oral cromolyn 100 mg qid for children 2 to 12 yr old (not to exceed 40 mg/kg/day) should be given. No effective treatment is available to reduce the number of tissue mast cells. The solitary mastocytoma should be surgically excised.

Acrodermatitis enteropathica¹⁹

Acrodermatitis enteropathica is a rare congenital disorder characterized by diarrhea, an inflammatory rash around the mouth and/or anus, and hair loss. The inheritance is autosomal recessive. Symptoms usually occur within the first few months after birth. Both males and females are equally affected. In some cases, discontinuation of breastfeeding appears to trigger the disease. This has led researchers to believe that human milk may affect zinc bioavailability. However, the disease is also found in healthy breast-fed infants, thus the exact mechanism of the metabolic defect remains unclear.

An acquired form, although extremely rare, is also possible in children who are on total parenteral nutrition (TPN). For the last few years

since the disease has been recognized, TPN has included zinc supplementation.

Clinical features include

- Red and inflamed patches of dry and scaly skin, particularly around body openings such as the mouth, anus, and eyes, and the skin on elbows, knees, hands, and feet. It may look like atopic dermatitis.
- Patches evolve into crusted, blistered, pus-filled and eroded lesions.
- There is usually a sharp demarcation between the affected area and normal skin.
- Skin around nails becomes inflamed and there may be abnormal nail growth.
- Hair loss on the scalp, eyebrows and, eyelashes.
- Conjunctivitis.
- Sensitivity to light.
- Loss of appetite.
- Diarrhea, mild or severe.
- Irritability and withdrawal.
- Blood zinc level is abnormally low.

Acrodermatitis enteropathica is easily and effectively treated with zinc supplementation. Daily oral zinc supplementation will need to be continued for life. Secondary bacterial and/or fungal infection of lesions require appropriate antibiotic therapy. If acrodermatitis enteropathica is left untreated, symptoms of zinc deficiency progress further and may even result in death.

Sclerema neonatorum ²⁰

It is seen in a preterm, ill neonate. Almost always associated with metabolic acidosis, hypothermia, and infection, the mortality rate of this condition is around 60%. The disease presents as woody induration of the skin and subcutis over the buttocks, cheeks, thighs, and lower legs. Histopathology helps to differentiate from subcutaneous fat necrosis that has a good

prognosis. Sclerema does not show necrosis but shows cleft-filled fat cells that contain triglyceride crystals. The presence of erythema, bluish discolouration of the skin, focal distribution, and the histologic presence of inflammatory cells, giant cells, and calcium crystals may differentiate subcutaneous fat necrosis. Children with sclerema may respond to corticosteroids with packed cells transfusion.

Leiner's disease ²¹

Leiner's disease occurs in infants and is characterized by severe generalized seborrhoeic dermatitis, recurrent diarrhea, recurrent skin and internal infections, and failure to thrive. It may be present at birth but more commonly develops within the first few months of life. It appears to be more common in females than males and in breast-fed infants.

The precise cause of Leiner's disease remains unknown but it is known that a defect in the body's complement system has a major role to play in its development. The complement system is a vital part of the body's immune system, and in Leiner's disease an inherited dysfunction or deficiency in the C5 component of complement alongside other factors have been implicated. Other immune deficiencies may present in an identical fashion in infancy.

The condition usually starts off as a scaly rash on the scalp, face or napkin area. Very rapidly it spreads to other parts of the body. The affected area is bright red and may look swollen. Infants appear uncomfortable but do not itch. Other symptoms include recurrent diarrhea, infant not thriving or gaining weight, and local skin infections. There is also a risk of developing more severe infections that may lead to pneumonia, meningitis and septicemia.

Initially affected babies may need to be hospitalized to manage fluid and heat loss. Bland emollients may be used to treat the rash.

Providing adequate nutrition is also an essential part of treatment. Biotin, a water-soluble vitamin that is found naturally in foods such as liver, kidney, meat, milk, egg yolks and vegetables, appears to be useful in treating Leiner's disease.

Acute skin failure (ASF) ²²

What are the consequences of ASF?

These include the following

- Loss of barrier function
- Loss of immunological function
- Loss of fluids
- Increased cutaneous blood flow
- Increase in energy expenditure
- Impaired thermoregulation
- Increased susceptibility to infections
- Increased percutaneous absorption
- Development of multi-organ failure

Management of ASF

The principles of management are as follows

- Fluid and electrolytes balance
- Hemodynamic balance
- Prevention of sepsis
- Treatment of infection
- Nutritional supplementation
- Maintenance of environmental temperature
- Anticoagulant therapy in cases of DIC
- Skin grafting in conditions such as TEN

Criteria for poor prognosis of ASF

- Younger children, particularly the neonate
- Extensive of skin involvement
- Altered states of consciousness
- Increased respiratory rate
- Increased cardiac rate
- Drop in systolic blood pressure
- Reduced neutrophil counts
- Decreased urinary output

Monitoring of children with ASF ²³

Centres specialized in management of ASF have created what is known as 'Simplified Acute. Physiological Scores' (SAPS), a scoring system built-up in order to predict the outcome of severe skin disorders. This system takes into consideration a combination of several clinical and biological parameters following admission of the patient into the ward.

The parameters include

- Hourly recording of respiratory rate, pulse rate, blood pressure, and urine output volume
- Fourth hourly observation of body temperature, consciousness, and gastric emptying
- Daily monitoring of body weight, extension of skin involvement, fluid losses, blood chemistry, and blood gas analysis. The urine is examined for glycosuria
- Bacteriology of skin lesions at least once every other day

Intensive skin care units (ISCU)

From the brief description of the disease entities mentioned above and the concept of ASF, it is needless to say that there is a definite need for specialized ISCUs in every teaching hospital and tertiary health care centres. However in countries such as India the economics of such ISCUs do not work out to be a feasible project. This should not deter our enthusiasm. But the emphasis should be on building the perception of teamwork that is the key to successful outcome of pediatric dermatological emergencies. There is always scope for innovation, indigenization, and improvisation. They are the determinants that drive us through our search for excellence.

Conclusion

Unsurprisingly intensive care is absolutely necessary in a wide range of dermatoses. Acute

skin failure occurs secondary to several changes such as fluid loss, electrolyte imbalance, infections, etc. in fact cardiac or renal failure may be the terminal eventuality of acute skin failure. Diseases such as toxic epidermal necrolysis have to be managed just as a case of extensive burns. Precise watching of haemodynamic and cutaneous bacteriological data does assessment of prognosis. The guidelines of treatment include careful attention to electrolyte equilibrium, nutrition, aseptic precautions, energy expenditure, and environmental temperature. All these therapeutic measures should best be given in specialized wards that will get to be known as 'intensive skin care units' in future.

Points to remember:

1. *There are a wide range of dermatological emergencies*
2. *Intensive care is absolutely necessary in these disorders*
3. *Acute skin failure occurs secondary to several changes such as fluid loss, electrolyte imbalance, infections, etc. in fact cardiac or renal failure may be the terminal eventuality of acute skin failure.*
4. *Toxic epidermal necrolysis have to be managed just as a case of extensive burns.*
5. *Management includes careful attention to electrolyte equilibrium, nutrition, aseptic precautions, energy expenditure, and environmental temperature. All these therapeutic measures should best be given in specialized wards that will get to be known as 'intensive skin care units' in future.*

References

- 1 Roujeau JC, Revuz J. Intensive care in dermatology In: Recent advances in dermatology. No.8. Eds by Champion RH and Pye RJ, Churchill Livingstone, London, 1990; pp 85-99

2. Feingold DS. Gangrenous and crepitant cellulitis. J Amer Acad Dermatol 1982; 6: 289-299.
3. Snyder RA and Eliaz PM. Toxic epidermal necrolysis and staphylococcal scalded skin syndrome. Dermatologic Clin 1988; 235-248.
4. Whitley RJ, Namiaz AJ, Soong SJ, *et al.* Therapy of Neonatal Herpes simplex virus infection. Paediatrics 1980; 66: 495-501.
5. Jacobs MI, Magid MS, Jarowski CT. Disseminated Candidiasis. Arch Dermatol 1980; 116: 1277-1299.
6. Kramer MS, Leventhal JM, Hutchinson TA, *et al.* Adverse drug reactions. JAMA 1979; 242: 623-628.
7. Kawasaki T, Kosaki F. A new infantile acute febrile mucocutaneous lymph node syndrome (MLNS) in Japan. Paediatrics 1974; 54: 271.
8. Ramsay DL, Hurley HJ. Papulosquamous eruptions and exfoliative dermatitis. In Dermatology. Eds, by Moschella SL and Hurley HJ, WB Saunders, Philadelphia yr; pp
9. Tonnesen MG, Soter NA. Erythema multiforme. J Am Acad Dermatol 1978; 1: 357-364.
10. Heinbeck DM, Hengrave LH, Marvin JA, *et al.* Toxic epidermal necrolysis. A step forward in the treatment. JAMA 1985; 257: 2171-2175.
11. Lentz CL, Altman J. Lamellar ichthyosis. The natural history of collodion babies. Arch Dermatol 1968; 97: 3-5.
12. Ognibene AJ, Dito WR. Chronic meningococcemia: further comments on the pathogenesis of associated skin lesions. Arch Intern Med 1964; 114: 29.
13. Grogen TM, Odom RB, Bargeta JH. Graft versus host reaction. Arch Dermatol 1977; 113: 806-812.
14. Briggaman RA. Hereditary epidermolysis bullosa with special emphasis on newly recognized syndromes and complications. Dermatologic Clin 1983; 1: 263-280.

15. Chorzelski TP, Jablonska S. IgA linear dermatosis of childhood. *Br J Dermatol* 1979; 101: 535-542.
16. Lang PG, Dubin HV. Hemangioma-thrombocytopenia syndrome: A disseminated intravascular coagulopathy. *Arch Dermatol* 1975; 111: 105-107s
17. Vogel JM, Vogel P. Idiopathic histiocytosis: A discussion of eosinophilic granuloma, the Hand-Schuller Christian disease, and Letterer-Siwe syndrome. *Semin Hematol* 1972; 9: 3-19.
18. Demis DJ. The mastocytosis syndrome. *Ann Intern Med* 1963; 59: 194-206.
19. Moynahan EL. Acrodermatitis enteropathica: A lethal inherited human zinc-deficiency disorder. *Lancet* 1974; 2: 399-400.
20. Kellum RE, Ray TL, Brown GR. Sclerema neonatorum. *Arch Dermatol* 1968; 97: 372-375.
21. Miller ME, Koblenzer PJ. Leiner's disease and C5 dysfunction. *J Paediatr* 1972; 80: 879-88.1
22. Shuster S. Systemic effects of skin disease. *Lancet* 1967; 1: 907-912.
23. LeGall JR, Loirat P, Alperovitch A, *et al.* A simplified acute physiological score for intensive care unit patients. *Critical Care Medicine* 1984; 12: 975-977.

BOOK REVIEW

| | |
|-------------------|--|
| Name | Pediatric Nephrology 4 th Edition, 2005 |
| Editors | Dr. R.N. Srivastava Dr. Aravind Bagga |
| Review | Two senior pediatric nephrologists of India have come out with 4 th Edition of their book Pediatric Nephrology, which is already popular among postgraduates and practicing pediatricians for its simple but elegant presentation of various intrinsic aspects of pediatric nephrological care. On going through the book, one can appreciate the inclusion of recent advances in every chapter compared to its third edition, which is correctly reflected in an increase of about 100 pages over its previous edition. Every aspect of Pediatric Nephrology is well dealt by experienced authors. Color photographs are new additions to this book. Topics on anatomy, physiology, evaluation of renal function and imaging and diagnostic modalities are well dealt with in a simple and understandable way. All essential aspects of clinical nephrology including developmental anatomy to malignant disorders are discussed in a classical way by the authors. A special content on neonatal nephrology justify the book to be included as a full and complete reference on pediatric nephrology. Algorithmic approaches throughout the book are a welcome step for easy understanding. Including key points separately in every topic has made this book a special one. We recommend this book on Pediatric Nephrology for every medical personnel interested in learning finer aspects of pediatric renal medicine. |
| Publishers | M/s. Jaypee Brothers Medical Publishers (P) Ltd., EMCA House, 23/23 B Ansari Road, Daryaganj, New Delhi – 110 002. |
| Price | Rs.495/- |

NEWS AND NOTES

12th East Zone Pedicon & 20th Assam State Pedicon

Date: 19-20 November, 2005 **Venue:** Guwahati, Assam

Contact: Dr. Garima Saikia, 'Child Health Clinic', AK Azad Road, Rehabari, Guwahati 781 008, Ph.0361-2260177 (r), 2544310 (c), Cell: 98640-13453, 94351-17865, Email: gsaikia2@rediffmail.com

MANAGEMENT UPDATE

BACTERIAL MENINGITIS IN THE POST NEONATAL PERIOD

*** Potharaju Nagabhushana Rao**

**** Potharaju Anil Kumar**

Abstract: *Despite advances in antibacterial therapy, bacterial meningitis is associated with high morbidity and mortality rates even in developed countries because consequences are potentially devastating and isolates with reduced susceptibility to penicillin are found in increasing numbers. Causative bacteria depends on age, route of infection and risk factors. Clinical presentation depends on age. The laboratory gold standard is the isolation of the causative bacteria from the cerebrospinal fluid. Repeat LP is not usually indicated if the patient makes uneventful recovery. In complicated meningitis neuroradiological examination plays a fundamental diagnostic role. Management of drug resistant meningitis and recurrent meningitis require special care.*

Key words: *Bacterial meningitis, pyogenic meningitis, postneonatal.*

Meningitis is an inflammation of the meninges, the membranes that cover the brain and spinal cord. Pathologically, acute bacterial meningitis (ABM) results in congestion and hyperemia of the pia-arachnoid and distention of the subarachnoid space by an exudate containing polymorphonuclear neutrophils. Most cases of

meningitis are caused by viruses and present with symptoms that are typically milder and resemble the flu. Bacterial meningitis is a medical emergency. Other infectious causes of meningitis include

- a. Viruses: Enteroviruses (Echo, Polio, Coxsackie), Arboviruses (Japanese Encephalitis), Herpes simplex type 2, Lymphocytic choriomeningitis, Varicella zoster, Mumps
- b. Fungi: Coccidioidomycosis, paracoccidioidomycosis, Cryptococcus, Candida, Aspergillus, Zygomycetes
- c. Protozoa: Amebic (Naegleria, Acanthameba), Trypanosomiasis
- d. Helminthes: Angiostrongylus

Causative organisms and route

H. influenzae, Streptococcus pneumoniae and Neisseria meningitidis are the common bacteria causing meningitis in under five year old children¹. Currently, Streptococcus pneumoniae (pneumococcus) and Neisseria meningitidis (meningococcus) are the leading causes of bacterial meningitis, which can occur as isolated cases or epidemics. Streptococcus pneumoniae is associated with highest mortality. Meningococcus infects humans only, it colonizes the nasopharynx and is the most common cause of bacterial meningitis between the ages of 2 and 18 years. Serogroups B and C each account for nearly half of cases. Haemophilus influenzae type b (Hib) persists as a major cause of pediatric meningitis and pneumonia in developing countries where Hib conjugate vaccines are not used².

* Prof. & Head of Department of Neurology, Osmania Medical College and Chief Pediatric Neurologist, Niloufer Hospital, Hyderabad

** Secunderabad Brain Clinic, Hyderabad

Table 1. Causative bacteria depending on age

| Age Group | Common Organisms |
|------------------------|--|
| 1 – 3 months | Group B streptococcus (especially <i>S.agalactiae</i>), <i>Escherichia coli</i> , <i>Listeria monocytogenes</i> |
| > 3 months-adolescence | <i>Neisseria meningitidis</i> (<i>Meningococcus</i>) <i>Streptococcus pneumoniae</i> <i>Haemophilus influenzae</i> |
| Any age | <i>Streptococcus pneumoniae</i> |
| Immunodeficient | <i>Listeria monocytogenes</i> , Gram negative organisms |

Bacteria may reach the leptomeninges and produce meningitis by the hematogenous route (most frequently), by the contiguous route and by direct (either traumatic or iatrogenic) inoculation. Causative organism depends on the age (Table 1), the route of entry and underlying risk factors (Table 2).^{3,4} Etiology in 1-2 month old babies is similar to neonates and includes bacteria from maternal flora and the environment to which the infant is exposed. Recurrent meningitis has different etiology⁵.

Recurrent meningitis has different etiology and includes head injury with CSF leak, Mollaret's meningitis (Herpes simplex DNA demonstrated in CSF by PCR), chronic systemic disease and brain tumor⁵.

Useful points in history

A detailed history includes vaccination history, recent infections (75% will have recent upper respiratory tract infection which up regulate Platelet Activating Factor receptor to which pneumococci adhere), known contact with someone with meningitis, recent travel, head trauma or cranial surgery and maternal obstetric history if child < 3 months, including maternal group B streptococcus status if known, recent use of antibiotics, drug allergies and medical history.

Common presentations

The presentation could be fulminant (a few hours) acute (1-24 hours), sub acute (1-7 days) or insidious (> 7 days). Clinical presentations vary and depend on age, duration of illness, patient's response to infection, whether prior antibiotics have been used and the infecting organism.

Clinical features are due to infection, vascular obstruction (infarction, necrosis, lactic acidosis), hypoxia, bacterial invasion (cerebritis), toxic encephalopathy (bacterial toxins), elevated ICP, ventriculitis and transudation (subdural effusion). The diagnosis may be difficult as history and presentations can be vague and nonspecific. Features include fever or hypothermia, irritability, high pitched cry, lethargy, altered mental state, seizures, photophobia (older children), apnea, poor feeding and vomiting. A high index of suspicion for meningitis must exist in sick, febrile or hypothermic young infants with or without the above features. Bulging fontanelle (evidence of raised intracranial pressure), diastasis (widening) of sutures or acute increase in head circumference are more useful in children 2 – 12 months of age.

Symptoms become more CNS specific after the age of 3 months. Acute presentations include

Table 2. Causative organisms depending on the route of entry and underlying risk factors

| Route/Risk Factors/Remarks | Pathogen |
|---|--|
| Hematogenous route | 1-3 months age group: Gram-negative rods (Escherichia coli K1, Citrobacter, etc.) group B streptococci, Listeria monocytogenes. Children and adults: Streptococcus pneumoniae, Haemophilus influenzae, Neisseria meningitidis |
| Skull fracture | Staphylococci, Pneumococci, Gram negative bacilli, Mixed infection, Recurrent infection |
| Neurosurgery (Post-operative patients frequently have headache and signs of meningeal irritation and pyrexia caused by blood in the subarachnoid space. Prolonged fever and reduced consciousness level should suggest an infective cause). | Gram negative bacilli (Escherichia coli, Klebsiella pneumoniae, Proteus spp, Enterobacteriaceae spp, Acinobacter spp, Pseudomonas and Serratia spp), Staphylococcus aureus, drug-resistant Streptococcus pneumoniae. |
| CSF leak | Pneumococci (Recurrent Pneumococcal meningitis should suggest CSF leak) Gram negative bacilli, mixed infection |
| CSF shunt | Coagulase negative Staphylococci (Staphylococcus epidermidis etc), Staphylococcus aureus and Gram negative bacilli |
| Sickle cell disease, cirrhosis of liver, Splenectomy, sickle cell anemia | Pneumococcus |
| Diabetes mellitus | Pneumococcus, Staphylococcus, Gram negative bacilli |
| Uremia (Due to non-specific manifestations and slow evolution, bacterial meningitis is commonly misdiagnosed as uremic encephalopathy) ³ . | Pseudomonas aeruginosa and coagulase-negative Staphylococcus |
| Cochlear implants ⁴ | Streptococcus pneumoniae and nontypable Haemophilus influenzae |
| Immune defects Neutropenia Lymphopenia (lymphomas, transplant recipients, AIDS) Humoral (favors infection with capsulated bacteria) | Pseudomonas aeruginosa, Enterobacteriaceae spp and Aspergillosis Listeria, Cryptococcus meningitis, Toxoplasma, Herpes virus, Mycobacteria Pneumococci, Hemophilus, Meningococci, Enterobacteriaceae spp and Mixed infection |
| Late complement deficiencies | Neisseria spp |
| Properdin deficiency | Meningococcus |
| Pregnancy and perinatal period | Listeria, Streptococci |
| Chronic lymphatic leukemia, treated lymphomas, radiotherapy and chemotherapy | Pneumococci, Meningococci, Hemophilus and Multiple organisms |
| Contiguous infectious focus(eg.otomastoiditis sinusitis) | Staphylococci, Streptococci and Pneumococci |
| Severe malnutrition, immunodeficiency and anatomical defects | Staphylococcus, Salmonella, Pseudomonas |
| HLA-B12 haplotype | H. influenzae |

fever (~ 50% in infants, ~ 45% in older children), neck stiffness (60 – 80%, more useful in children beyond 3 years of age) and back pain, Kernig's sign and Brudzinkin's sign are due to reflex muscle spasm to reduce pain on stretching the inflamed spinal nerves and roots and may be present in older children. Their absence does not exclude meningitis. Inflammation of cranial nerves causes dysfunction of III, VI, VII and VIII cranial nerves.

Focal neurological signs indicate vascular occlusion (arteritis, cerebral venous thrombosis), subdural collection, cerebritis, abscess formation or raised ICT with herniation.

Papilledema in uncomplicated early bacterial meningitis is rare. The presence of papilledema within a day or two of presentation suggests ruptured abscess causing pyogenic meningitis or hitherto undetected chronic meningitis like tuberculous meningitis and if it appears after a few days of pyogenic meningitis, it suggests complications like venous sinus thrombosis or subdural empyema. A swollen optic disc associated with marked reduction of visual acuity may indicate septic optic neuritis.

Raised ICT is very frequent. Rise is maximal within initial 48 hours with endangering cerebral ischemia due to decreasing cerebral perfusion. Fulminant presentation is seen with *Neisseria meningitidis*. Features of Raised Intracranial Tension (ICT) include bulging fontanelle, decreasing level of consciousness (due to brainstem compression), an abnormal pupillary reaction to light –asymmetrical reaction, or unreactive pupils, abnormal oculocephalic (doll's eye) reflex, abnormal respiratory pattern, viz. neurogenic hyperventilation, shallow, ataxic or apneic breathing, 'decorticate posturing', and 'decerebrate posturing', which may be spontaneous, or a response to pain and rising blood pressure with falling heart rate. Cushing's

triad of high BP, high respiratory rate and low heart rate usually occurs in later stages and should always raise a suspicion of raised ICT.

Meningococcal meningitis may occur with or without other manifestations of invasive meningococcal infection or meningococcemia. Characteristic skin rash of meningococcemia is usually seen on trunk and legs and includes palpable purpura or ecchymoses with irregular margin due to associated vasculitis. Hypotension or fatal shock may occur (Waterhouse Friderichsen syndrome) due to hemorrhagic infarction of the adrenals in the setting of overwhelming clinical sepsis and usually indicates meningococcal infection but rarely *Streptococcus pneumoniae*⁶ or any other severe sepsis.

Seizures: Seizures are seen in less than 40%. Generalized seizures during initial 4 days have no prognostic significance. The younger the brain, the more likely a seizure is provoked by infection and pyrexia and so the more common the seizures are. Multifocal seizures may occur due to electrolyte imbalance (Syndrome of Inappropriate Secretion of Anti-Diuretic Hormone-SIADH) or major organ dysfunction due to sepsis. Early recognition and treatment of generalized seizures in a metabolically compromised child is important due to the risk of serious sequelae. Persistent focal seizures or Todd's palsy indicate subdural effusion/empyema /abscess/vascular lesions (infectious vasculitis) such as arterial infarct, cortical vein thrombosis with venous infarcts/dural sinus thrombosis/bacterial encephalitis. No child develops late seizures unless there were acute seizures. Factors associated with seizures during acute bacterial meningitis include disturbed consciousness on admission (may signify an underlying encephalitis), abnormal neuroimaging findings, and low glucose and high concentration of total proteins in cerebrospinal fluid⁷. Bacterial meningitis may also present as acute torticollis⁸.

Minimising delay in diagnosis: To avoid a delay in the diagnosis of meningitis, a high index of suspicion should be maintained. Meningitis must be considered in any child with unexplained fever, seizures in association with fever, particularly if under 12 months, prolonged in nature or refractory to management. The presence of an apparent explanation for fever, e.g. pharyngitis or otitis media does not rule out the possibility of meningitis. Apparent improvement with paracetamol is not helpful in excluding the diagnosis.

Diagnostic tests

The laboratory gold standard for establishing the diagnosis of bacterial meningitis is the isolation of the causative bacteria from the cerebrospinal fluid (CSF). However, laboratory diagnosis is often made using the combination of blood and/or CSF cultures along with Gram stain and chemical analysis of the CSF.

Lumbar puncture (LP) : CSF analysis should be performed once the diagnosis of meningitis is suspected and after the patient is stabilized. Blood for glucose must be drawn and a secure IV line started before starting the LP. Simple aseptic precautions under- taken before the procedure prevent iatrogenic meningitis⁹.

Child must be assessed every 15 minutes for the next 4 hours and hyperosmolar agents administered if there is neurologic deterioration.

If there are reasons to delay LP (like clinical diagnosis of febrile seizure, infection / anatomical abnormality at LP site, unstable cardiorespiratory status, status epilepticus, raised ICT signs especially decerebrate or decorticate posturing, abnormal reaction of pupils, focal seizure, marked neck stiffness or neuroimaging showing shift of midline structures, obliteration of CSF pathways, herniation) and bacterial meningitis is clinically suspected, blood must be drawn for culture (useful in 66% of cases), antibiotics given

prior to the LP, a CT scan obtained and LP performed 8-24 hours after both antibiotics and antiedema treatment are started. With this procedure, the risk of LP is lessened, and the CSF may still be purulent. However, if the correct antibiotic is chosen, cultures of CSF will be sterile within 48 hours.

Diffusely elevated ICT occurs in almost all cases of bacterial meningitis and is not in itself a contraindication to LP. The decision to perform cranial computed tomography (CT) before the LP delays the diagnosis. Although concerns about herniation following an LP exist, herniation is unlikely in children unless they have focal neurological findings or are comatose. A CT scan cannot rule out raised intracranial pressure and a normal CT does not absolutely exclude subsequent risk of herniation.

Interpreting the CSF : White cells in CSF: Examination of any CSF samples taken is URGENT. Any delay will not give correct cell count. The presence of polymorphonuclear (PMN) cells is always abnormal and if present, suggests bacterial meningitis or rarely, early stages of tuberculous meningitis and viral meningitis although lymphocytosis is more commonly seen in the latter two conditions. In partially treated bacterial meningitis, the relationship between PMNs and lymphocytes may be reversed. In tuberculous (TB) meningitis, the total WBC is usually $< 500 \times 10^6/L$ and lymphocytes predominate.

CSF glucose concentration: Changes in the CSF glucose level follow changes in the blood glucose by about 30 minutes. So, the best way is to draw blood glucose and then draw CSF 15-30 minutes later so that the ratio can be accurately calculated for interpretation. Hypoglycorrachia is due to decreased glucose transport by the cerebral tissue, utilization of glucose by inflammatory cells and the pathogen. CSF glucose $< 2.2 \text{ mmol/L}$ is found in about $\frac{2}{3}$ of patients with bacterial meningitis.

CSF: blood glucose ratio <0.3 is found in 70%. Very low levels of CSF glucose are found in overwhelming infection, fungal and malignant meningitis. However, a normal glucose does not exclude meningitis. While the CSF glucose rarely influences treatment decisions, the CSF glucose level was found useful in the following situations¹⁰: patients pre-treated with antibiotics, CSF pleocytosis (suggests the most likely class of organism), patients > 8 weeks of age and patients at risk of unusual organisms. In bacterial meningitis other than that caused by *Neisseria meningitidis* and independent of the duration of symptoms prior to diagnosis, CSF glucose levels are significantly lower in patients developing a sensorineural hearing loss compared to controls¹¹.

CSF protein concentration: Raised CSF protein is due in part to increased vascular permeability (disruption of blood brain barrier) resulting in leakage of albumin rich fluid from the capillaries and veins traversing the subdural space. Continued transudations result in subdural effusions. 90% of patients with bacterial meningitis will have elevated protein levels.

Traumatic tap: Traumatic LP complicates the interpretation of CSF changes. The protein levels may be elevated in a traumatic tap. Methods for correction for the presence of RBC and protein elevation are proposed (approximately $0.01 -$

0.015 g/L increase in protein levels for every 1000×10^6 /L RBCs in uncentrifuged CSF samples). For every 500 RBC in the CSF, one WBC is acceptable. However this depends on the peripheral white and red cell counts. A more precise formula to estimate the WBC in CSF has been described¹². But it is more practical to rely on the bacteriologic result rather than to attempt to interpret the CSF leukocyte and protein results of a traumatic LP.

Gram stain: This is the best single test for rapidly diagnosing bacterial meningitis and initiating appropriate therapy (Table 3). In untreated bacterial meningitis, CSF Gram stains reveal bacteria in about 50% to 80% of cases and cultures are positive in at least 85% of cases. Occasionally, the Gram stain will be positive despite the absence of pleocytosis. However, sensitivity of both gram stain and cultures decreases to less than 50% in patients already taking antibiotics, but other CSF indices may still indicate a likely bacterial infection. In patients suspected of having meningitis, blood cultures should always be done because the organism can be cultured in 66% cases and occasionally they may uncover a pathogen that was not found on CSF cultures.

CSF changes after starting antibiotics: Antibiotics may sterilize the CSF within 1 hour

Table 3. Gram stain results of common bacteria causing community acquired bacterial meningitis

| Result of CSF Gram stain | Organism to be suspected |
|---|---------------------------------------|
| Gram positive cocci resembling streptococci | Group B streptococcus |
| Gram positive diplococci or Gram Positive Cocci resembling Streptococci | <i>Streptococcus pneumoniae</i> |
| Gram negative diplococci or gram negative cocci | <i>Neisseria meningitidis</i> |
| Gram negative cocco-bacilli | <i>Haemophilus influenzae</i> |
| Gram negative rods | Enterobacteriaceae e.g. <i>E coli</i> |
| Gram positive rods | <i>Listeria monocytogenes</i> |

in meningococcal meningitis and within 4 hours in pneumococcal meningitis and the cell response changes to lymphocytes within 24 hours. However, instituting antibiotics 1-2 hours prior to LP does not decrease the diagnostic sensitivity if the CSF culture is done in conjunction with blood cultures. But, CSF protein may continue to be high and CSF glucose may be low for 2 weeks or longer despite curative therapy.

Repeat LP: is not usually indicated if the patient makes uneventful recovery. A repeat LP at 24 – 48 hours may be indicated when clinical indicators of meningitis are present but initial CSF examination is normal. When the causative

organism is relatively difficult to treat (e.g., enteric gram-negative rods, *Listeria*, *Staphylococcus aureus*, β -lactam resistant *Streptococcus pneumoniae*), an LP should be done 72 hours after starting antibiotics to confirm sterilization of CSF. Rare indications include lack of clinical response, persistent fever, unusual etiologic organism or suspicion of antibiotic resistance. Persistence of the organism in the CSF beyond the expected interval implies a need to change the antibiotic or presence of an occult para-meningeal focus of infection seeding the CSF. An LP at the conclusion of therapy has not proved useful in predicting those patients who will relapse.

Table 4. Possible additional tests based on clinical presentation

- a. Platelet count, coagulation profile including fibrin degradation products - if there is shock, rash, or bleeding diathesis. DIC must be suspected.
- b. Erythrocyte sedimentation rate and C-reactive protein as inflammatory markers add useful information on clinical progress¹³.
- c. Blood glucose, urea, electrolytes and serum calcium, if seizures are refractory.
- d. Serum and urine sodium must be monitored every 8-12 hours during the first 2 days if SIADH is suspected. If patient has hyponatraemia, SIADH or cerebral salt wasting syndrome (CSWS) is possible.
- e. Plasma osmolality and Urinary osmolality.
- f. CT scan of Head - Indicated if space occupying lesion is suspected (Patient should be clinically stable.)
- g. Mycobacterium tuberculosis (MTB) stain - if Tuberculous Meningitis is suspected. Adequate volumes should be obtained for mycobacterial culture – aim for 5 –10 ml minimum. Concentration methods / repeat LP may be necessary.
- h. Scrapings of skin lesions – In meningococcal purpura. Gently derroof the skin lesion with a needle. Roll the sterile swab over the base of the lesion and then onto a glass slide and examine by Gram stain. Collect another swab and place into Stuart's Transport media for culture.
- i. Cryptococcal stain - Immunocompromised patients including HIV patients. (Gram stain is a good screening test as cryptococcus appears as large gram positive cocci. India ink can then be used to identify Cryptococcal capsule followed by latex agglutination for identifying cryptococcal antigen).
- j. Renal Function Tests and Liver Function Tests – Sepsis causes renal and hepatic dysfunction.

Table 5. More expensive Tests (Rarely required)

| Tests | Comments |
|--|--|
| Bacterial antigen detection in CSF | Indicated if previous antibiotics used. Can identify <i>S.pneumoniae</i> , <i>N. meningitidis</i> , <i>H influenzae</i> type b, and group B streptococcus. Negative results for a specific bacterial antigen do not rule out bacterial meningitis. |
| Cryptococcal antigen | Immunocompromised patients including HIV patients. |
| Beta-glucuronidase activity in CSF | The enzyme activity is increased early in the disease, even when the other laboratory parameters from the CSF remain normal. It is a reliable indicator of bacterial meningitis ¹⁴ . |
| Latex particle agglutination | For rapid diagnosis of <i>Coccidioidomycosis</i> , <i>Histoplasmosis</i> . Latex agglutination studies identify no additional cases of bacterial meningitis beyond those identified by culture in pretreated patients ¹⁵ . |
| Counterimmunoelectrophoresis | Detects bacterial antigen within 1-2 hours. |
| Meningococcal PCR | Only if any prior antibiotics were used. |
| PCR (Viruses. E.g., Enteroviruses) | If viral meningitis is suspected. Used only in reference laboratories. |
| Mycobacterium tuberculosis(MTB)PCR | Adequate volumes (5–10 ml minimum) should be and culture obtained for mycobacterial culture |
| Meningitis in cochlear implant recipients | Immunological evaluation |
| Viral culture | If CSF pleocytosis is present and viral meningitis is suspected |
| <i>Neisseria meningitidis</i> IgM | May be helpful for retrospective diagnosis. |
| Serology for Japanese Encephalitis | Requires convalescent serology |
| Enterovirus meningitis | |
| ELISA (detects bacterial or viral antibody) | Takes 3-36 hours for results. |
| Detection of pneumolysin (a toxin produced by <i>Streptococcus pneumoniae</i>) | Simple, low cost antigen detection assay for rapid diagnosis of pneumococcal meningitis, for routine use in the developing countries ¹⁶ . |
| A fluorescence-based multiplex PCR for the simultaneous detection of <i>Neisseria meningitidis</i> , <i>Streptococcus pneumoniae</i> and <i>Haemophilus influenzae</i> | Fast diagnosis ¹⁷ . |
| Broad-range 16S ribosomal DNA PCR detection. | May be useful when the suspicion of bacterial meningitis remains ¹⁸ . |
| Combur10 reagent strips. | In situations where facilities of routine laboratory testing are not available this can be of an immense help ¹⁹ . |

Investigations for all patients with suspected bacterial meningitis (Table 4, 5)

- a. Basic investigations include complete blood count (A normal WBC count does not exclude meningitis).
- b. S.electrolytes, blood glucose, renal function tests (monitor serum sodium to detect SIADH).
- c. Chest X-ray (for focus of infection)
- d. Cultures from throat, blood and urine

Neuroradiology

In complicated meningitis neuroradiological examinations play a fundamental diagnostic role. Neuroimaging is indicated if there are focal signs/seizures, if seriously raised ICT is suspected, if there is papilledema, lack of significant response to medical treatment, fever or coma persist, head circumference increases or when complications are suspected. Cranial sonography is most economical and easily available for young infants but use is limited. CT is usually preferred because it is cheaper than MRI, faster and can be done in ill patients with an airway. Additionally, there is a positive correlation between CT scan results and neurological signs²⁰. Ventricular imaging findings may be unremarkable or show ependymal enhancement on contrast if there is ventriculitis. Meningeal enhancement with contrast injection may be absent in viral meningitis and bacterial meningitis of children. In severe bacterial meningitis it is nevertheless usually present and is associated with distention of the subarachnoid space with widening of the interhemispheric fissure by the inflammatory exudate. On CT this distention is seen as an obliteration of CSF space due to the increased density of the exudate. Small ventricles and effacement of sulci imply brain swelling and raised ICT. Hydrocephalus results from malabsorption due to basal meningeal adhesions. Sediment in the posterior horns of the lateral ventricles indicates pus collection. Focal space

occupying lesions result from abscess or infarction due to arteritis or phlebitis. Subdural collections may be seen. Paranasal sinusitis or fracture may be detected.

MRI is the examination of choice in the assessment of parenchymal lesions due to its superior sensitivity. Meningeal enhancement is associated with a slight signal increase of both T1- and T2-weighted images (due to the high proteinaceous content of the exudate). Parenchymal foci of involvement are visible as T2 hyperintensities and they may represent arterial or venous infarcts or cerebritis. The presence or absence of conformity to a distinct vascular distribution, and the presence of venous T1 hyperintensities representing thrombosis (to be searched for in particular in the veins near the sagittal sinus) are features that assist in the differentiation of these entities. Sometimes differentiation of cerebritis from infarction may only become apparent with time as cerebritis typically evolves into a well formed abscess.

Hydrocephalus and its sequela, transependymal migration, are equally well demonstrated on CT and MRI but identification of an eventual site of obstruction benefits from the multiplanarity of MRI. Early/minimal transependymal migration is better demonstrated on MRI. Postcontrast imaging enables differential diagnosis between ependymitis (enhancement of the ependymal lining) and simple transependymal migration (no enhancement).

Subdural effusions and empyemas are also well documented on both CT and MR imaging studies. Differentiation between the two entities is possible on MRI on the basis of signal intensities (subdural effusion presents a CSF-like signal, whereas empyema shows hyperintensities on both T1 and T2 weighted images). Additionally empyema shows an enhancing membrane and it is usually associated with foci of parenchymal involvement.

CT myelography may be needed in dural leaks.

Repeated clinical and laboratory investigations may be necessary depending on the clinical situation.

Differential Diagnosis

A variety of noninfectious diseases (Table 6) have to be differentiated from pyogenic meningitis. Table 7 shows differentiating characteristics of common meningitides

Rash and Meningitis may be seen in

bacterial (Meningococcus, Pneumococci, Staphylococci, Hemophilus, Listeria) or Viral (Echo 9) infections. Myalgia and myocarditis may complicate Coxackie meningitis. HIV may have arthralgia and lymphadenopathy.

CSF in differential diagnosis (Table 8): In most cases, clinical indicators of meningitis or sepsis will be present²¹. No CSF test is fully reliable in distinguishing bacterial from non-bacterial meningitis. Postictal CSF abnormalities (pleocytosis or raised protein) are rare, and should not be readily accepted as a cause for an abnormal CSF²².

Table 6. Noninfectious meningitides to be considered in the differential diagnosis of bacterial meningitis.

| Non-infectious causes | Comments |
|--|---|
| Drug induced meningitis | NSAIDs, trimethoprim, immunoglobulin and some antibiotics, intrathecal drug administration. |
| Brain tumor | Epidermoid cyst leak contents into the CSF causing chemical meningitis. |
| Subarachnoid hemorrhage. | Chemical meningitis |
| Migraine | Lymphocytic pleocytosis in CSF. |
| Cerebellar tonsillar herniation or Uncal herniation or Subfalcial herniation in raised ICT | Present with rapid CVS and RS failure |
| Mollaret's syndrome | Recurrent lymphocytic and aseptic meningitis; may be associated with Herpes simplex virus. |
| Sarcoidosis | Long standing respiratory symptoms, bilateral hilar lymphadenopathy and hypercalcemia are associated. |
| SLE | Drug induced lupus DOES NOT cause CNS or Renal disease |
| Neoplastic Meningitis | Lymphoma, medulloblastoma, pineal tumors and germ cell tumors. Polarized light examination of neutrophils shows keratin fragments diagnostic of chemical meningitis secondary to spillage of the contents of a dermoid cyst or craniopharyngioma. Leukemia. |
| Behcet's disease | Genital ulcers, uveitis or erythema nodosum. |
| Whipple's disease | Multisystemic symptoms. |
| Vogt-Koyanagi-Harada syndrome | With inflammatory changes in uvea, retina, meninges and skin. Lymphocytic meningitis is seen in acute phase. |

Table 7. Clinical differentiation of common meningitides

| Characteristic | Viral Meningitis | Acute Bacterial Meningitis (TB, Fungal) | Chronic Meningitis |
|--------------------------|--|--|--|
| Onset | Acute (<1 day) | Acute (<1 day) or rarely fulminant (first symptom to death may be few hours) | Weeks to months |
| Headache | Prominent | Less prominent | Less prominent in initial stages. More prominent when weeks to months; hydrocephalus develops. |
| Level of Coma | Drowsy but coherent and cooperative | Deeper levels of coma, focal neurologic signs | Deeper levels of coma, focal neurologic signs |
| Raised ICT | Mild | More severe | More severe |
| Focal Neurological signs | No. (Focal signs or deterioration of sensorium indicates development of encephalitis). | Seen in 15%. | Most frequent |
| Prognosis | Benign and self limiting | Not very good | Not good |

The clinical presentations and CSF findings in children who have received previous antibiotics may be modified. The relationship between polymorphonuclear cells and lymphocytes in CSF may be reversed. Positive cultures can be obtained up to 4 hours after the first dose of antibiotic and bacterial antigens can be detected in CSF up to several days after initiation of therapy. The diagnosis of acute bacterial meningitis is delayed in children pre-treated with antibiotics but the complication rate is not necessarily increased²³.

Pyogenic or Tuberculous Meningitis? Patients with pyogenic meningitis, even if treated with oral or intramuscular antibiotics, usually have a polymorphonuclear CSF response. Some patients with pyogenic meningitis, immediately after intravenous antibiotics, have a predominant lymphocytic response in CSF and a sterile

culture. On the other hand, tuberculous meningitis, especially in infants, may present with a polymorphonuclear reaction in the CSF and blood and low CSF sugar. Rarely later stages of TBM may also present with neutrophilia. Usually, in about 30% of all cases of meningitis, there is diagnostic confusion between tuberculous meningitis and pyogenic meningitis. Yet both are serious life threatening infections requiring early aggressive treatment to prevent death and disability. Pyogenic meningitis is diagnosed if: (1) CSF is positive for C-Reactive Protein¹³ (2) CSF is positive for Gram stain / bacterial culture or (3) No basal enhancement on contrast CT scan, (4) there is a sustained response without antituberculous treatment. In case of doubt, child could be treated both for TBM and pyogenic meningitis. Later, treatment for TBM should be continued depending upon the response and other evidence of extracranial TB.

Table 8: CSF findings (usual ranges)

| | Appearance | Polymorphs per mm ³ | Lymphocytes per mm ³ | Protein (mg/dL) | Glucose (mg/dL) | Glucose (CSF : Blood ratio) |
|--|--|--|---|--|---|--------------------------------------|
| Normal | Clear | 0 | < 5 | < 45 | > 50 | > 0.6 |
| Pyogenic meningitis | Opalescent to frank pus | 100 – 10,000 or more. Usually 300-2000. >10,000 indicates ruptured abscess as the cause of pyogenic meningitis | < 100 | 100-500 | Decreased | < 0.4 |
| Partially treated pyogenic meningitis | Clear or opalescent | | 5-10,000 Neutrophils or Lymphocytes | 100-500 | Normal or decreased | Normal or decreased |
| Tuberculous meningitis | Opalescent. Fibrin web or pellicle (Cobweb) | Present in early stages | 250-500 | 45-500. parallels cell count increases with time | decreased | decreased |
| Viral meningitis | Clear unless cell count is >300 | Early in the course | 10 – 1000. in Lymphocytic Choriomeningitis ~10,000 | 40 - 100 | Normal. Decreased in 15-20% cases (reduced in Mumps, Herpes or other viral infections) | Normal |

Mixed meningitis: When pyogenic bacteria are introduced inadvertently during lumbar puncture of a child with TBM, causing mixed meningitis, the CSF misleadingly shows only TBM picture. If a child worsens within 1-2 hours after lumbar puncture, herniation must be suspected and when worsening occurs after 2 hours, superadded pyogenic meningitis must be suspected and investigated immediately.

Points to note

- CSF can be misleading in partially treated cases, early in overwhelming infections, especially with *Streptococcus pneumoniae*, where there can be poor neutrophil response, when the child is markedly leukopenic or immunosuppressed, when meningitis is caused by bacteria (*Listeria monocytogenes*, *Treponema pallidum*, *Borrelia burgdorferi*,

Leptospira interrogans) that induce a lymphocytic response rather than neutrophilic response.

- CSF becomes turbid when the leukocyte count exceeds about 300/mm³. 20% of patients of pyogenic meningitis have <250 leukocytes/mm³.
- Pleocytosis is absent when severe sepsis is associated with meningitis and is a bad prognostic sign.
- Gram stain and culture results are affected in partially treated pyogenic meningitis but not glucose and protein results.
- Gram stain and cultures are not affected by traumatic LP and are presented in Table XIII.
- Presence of RBC in CSF may imply Herpes Simplex meningoencephalitis provided a traumatic tap has been ruled out (by the 3 tube test).

A combination of the following CSF values predicts bacterial meningitis with 99% accuracy: WBC count >2,000/mm³, Neutrophil count >1,180/mm³, Protein level >220 mg/dL, CSF-serum glucose ratio <0.23, Glucose level <34 mg/dL. Wet smear for microscopy is useful for fungi and amoebae.

Treatment

Specific measures

General considerations: It is often difficult to distinguish viral from bacterial meningitis. As the clinical manifestations can be indistinguishable, it is practical to assume a bacterial cause in initial management. Empiric antibiotics selection is dependent on the likely bacterial organism and modified by factors such as antibiotic resistance patterns prevalent in the region. Subsequent therapy is based on culture and sensitivities^{24,25}. Antibiotics must be administered as soon as possible in order to prevent damage and/or death,

while other tests and imaging are being carried out since abnormalities of CSF and visible organisms in CSF will persist for more than 24 hours. Antibiotics must always be given intravenously.

Empiric antimicrobial therapy for bacterial meningitis: Current recommendations for empiric therapy are third generation cephalosporins, cefotaxime or ceftriaxone being the preferred antibiotics²⁶ before investigation results are available due to their efficacy against penicillin resistant *H. influenzae* type b and *Streptococcus pneumoniae*. Where affordability is a problem, Ampicillin plus Chloramphenicol is an economical substitute if there is no significant penicillin resistance²⁷. Table 9 and Table 10 summarize the important drugs' details.

Penicillin allergic patients: In patients with a history of serious allergic reactions to penicillin (i.e., bronchospasm, angioedema, or hives within 48 hours), useful alternative agents are chloramphenicol in known *H influenzae* type b or meningococcal meningitis, vancomycin in pneumococcal meningitis, and trimethoprim-sulfamethoxazole in suspected or proven *Listeria monocytogenes* infection. Panipenem-betamipron appears to be effective for the treatment of listerial meningitis²⁹.

Drug Resistance: It is increasing and requires special care (Table 10).

Chloramphenicol and Drug interactions: Phenobarbitone reduces chloramphenicol levels when both drugs are used together and phenytoin and chloramphenicol levels are both increased if both drugs are used in combination.

New drugs such as meropenem (also useful against penicillin resistant pneumococci and multidrug resistant *Pseudomonas*), cefpirome or trovafloxacin (hepatotoxic) may have a role but at present these are expensive and not in common use.

Table 9. Antibiotics used in Bacterial Meningitis

| Drug | Dose/kg/day IV only | No. of divided doses | Important side effect |
|--|-------------------------|----------------------------|--|
| Ampicillin | 300 mg | 4 | Primarily excreted by kidneys. Reduce dose in renal failure. |
| Benzylpenicillin | 60mg/kg (max 2.4g)IV | 6 | The most dreaded is anaphylaxis. |
| Ceftriaxone (Not active against bacteria causing neonatal meningitis, Listeria, S. aureus or anerobic bacteria, postneurosurgical patients and immunosuppressed hosts, and for Pseudomonas). | 100 mg | 2 | Ceftriaxone may cause reversible Cholelithiasis (diagnosed with ultrasound). |
| Cefotaxime | 200 mg | 4 | Same as ceftriaxone |
| Chloramphenicol ²⁸ | 100 mg | 4 | Bone marrow function must be checked thrice weekly by blood counts. |
| Vancomycin | 60 mg | 3-4 | “Red man” syndrome. Rapid infusion causes hypotension. |
| Nafcillin | 200 mg | 4-6 | Same as penicillin. Interstitial nephritis may occur. |
| Meropenem | 120 mg | 3 | It increases frequency of seizures. |

Duration of therapy: For Meningococcal infections-7 days, For H influenzae-10 days, For S.pneumoniae- 14-21 days. In infections with less sensitive organisms (enteric gram-negative organisms) or after trauma or surgery or when pockets of organisms infect tissues with poor perfusion, antibiotic therapy may have to be given for 3 weeks or longer (at least for 2 weeks after CSF sterilization which usually occurs within 2-10 days)). Therapy may be prolonged if clinical response is slow or complications occur. Though 7 day therapy in H influenzae has shown good results without steroid usage, it cannot be recommended when steroids are used. Longer individualized duration is required in cases of complications such as subdural empyema,

prolonged fever, persistence of meningeal signs of irritation or development of nosocomial infections. If any surgery is performed near the end of the therapy, the antibiotics are continued for at least 72 hours after surgery. In infections with less sensitive organisms (e.g., gram-negative organisms, Listeria monocytogenes, group B streptococci) therapy has to be for 2-3 weeks or longer.

Adjunctive therapy – Corticosteroids

The role of dexamethasone: Corticosteroids like methylprednisolone and dexamethasone inhibit the inflammatory host response (release of cytokines, toxic intermediates from brain cells, increased vascular permeability) evoked by rapid

Table 10. Drug Resistance

| Bacterium | Resistant to | Use |
|----------------------------|--|---|
| S pneumoniae ³⁰ | β-lactam antibiotics (e.g., ampicillin)*. cefotaxime and ceftriaxone vancomycin-tolerant | Cefotaxime or ceftriaxone Vancomycin and rifampicin Newer beta-lactam monotherapies (cefepime, meropenem, ertapenem), recently developed quinolones (garenoxacin, gemifloxacin, gatifloxacin, moxifloxacin) and a lipopeptide antibiotic (daptomycin) may have a role ³¹ . |
| Meningococci | Chloramphenicol penicillin | Cefotaxime or ceftriaxone Cefotaxime or Ceftriaxone |
| H. influenzae | Chloramphenicol. Ampicillin ³² | Cefotaxime or Ceftriaxone |
| Staphylococcus aureus | Methicillin | Cefotaxime or Ceftriaxone ³³ Linezolid ³⁴ . |
| Staphylococcus epidermidis | Methicillin | Vancomycin ^{35, 36} |

* Penicillin resistance should only be tested by using oxacillin discs and not ampicillin discs. For P.aeruginosa meningitis, the combination of intrathecal and intravenous amikacin should be used³⁷

lysis of bacteria in the CSF after administration of antibiotic. Adjuvant dexamethasone is unequivocally recommended in children with Haemophilus meningitis or pneumococcal meningitis³⁸. The benefit of adjunctive dexamethasone is likely to be greatest in patients who are otherwise healthy and present early with acute bacterial meningitis. Dexamethasone, before or with the first dose of antibiotic, is likely to be one of the most significant practice changes that has been of proven value in the developed world. Dexamethasone has no effect on Neisseria meningitidis meningitis³⁹. Children with Haemophilus influenza type B meningitis who were given dexamethasone had less fever, lower CSF protein and lactate levels, lower incidence of neurologic sequelae, including hearing loss. There is no basis for restricting the use of dexamethasone to more severe cases. A speculative concern is the reduced penetration

of vancomycin into the CSF with steroid use as vancomycin does not penetrate the non-inflamed meninges.

Limitations: A practical problem is how often can we diagnose H. influenzae and Streptococcus pneumoniae meningitis before giving the first dose of antibiotic? Secondly, it cannot be assumed that if dexamethasone is beneficial for H. influenzae and Streptococcus pneumoniae meningitis, it should be efficacious for other pathogens. The role of steroids in cephalosporin (cefotaxime or ceftriaxone) treated bacterial meningitis in developing countries should be further studied. Steroid use as adjunctive therapy in childhood meningitis remains controversial in the post-Hib vaccination era where Streptococcus pneumoniae (penicillin resistant) and Neisseria meningitidis have become the pathogens of concern in infants and children. Steroids must not be used in newborns (bacterial spectrum is

different, role of inflammatory mediators is not documented), suspected cerebral malaria (increases the severity), gram-negative bacillary meningitis, nonbacterial meningitis, aseptic meningitis or viral encephalitis (not useful), partially treated meningitis and undiagnosed meningitis or in areas with high penicillin-resistant pneumococcal invasive disease. Major concern is a potential decrease of antibiotics concentration in cerebrospinal fluid that may be detrimental in patients with meningitis caused by *Streptococcus pneumoniae* strains that are highly resistant to penicillin or cephalosporins. Adjunctive corticosteroid therapy is not recommended for bacterial meningitis in children vaccinated against H influenzae type b. There is insufficient evidence to support recommendations for the routine use of steroids for all children with bacterial meningitis treated with penicillin and chloramphenicol in developing countries.

The dose of dexamethasone is 0.15 mg/kg/dose every six hours intravenously in a single push 20 – 30 minutes before or at the time of first antibiotherapy and continued for 2 to 4 days. Complications like Gastrointestinal bleeding, hypertension, hyperglycemia could result from steroids. Rebound fever on stopping steroids may occur.

Supportive measures: Assessing the “Airway, Breathing, Circulation and Disability (level of consciousness)” is the first main concern.

Resuscitation: Airway and breathing: An open airway and adequate ventilation must be established. Supplemental oxygen should always be administered. If ventilation or oxygenation is inadequate, then respiratory support should be commenced by endotracheal intubation and ventilatory support.

Circulation: Fluid restriction is not an issue in the initial stabilization of children with

meningitis. Patients with evidence of shock should be treated with a rapid infusion intravenous/intrososseous crystalloid (Normal saline) 20ml/kg. Septic shock must be treated with fluid resuscitation and vasoactive drugs like dopamine, epinephrine and sodium nitroprusside. Considerations for fluid restriction (for SIADH) should only be undertaken after controlling shock.

Disability (level of consciousness): must be assessed. Multisystem monitoring in an intensive care unit till the patient is stable is necessary⁴⁰. Life threatening complications (septic shock, brain herniation) occur during initial 4 days and so admission to PICU and monitoring of cardiorespiratory status, fluid and electrolytes, frequent urine specific gravity, daily weights and frequent neurologic assessment is essential. Oral feeding should be withheld till patient is stable. When cerebral edema/raised ICT and shock (tachycardia, reduced skin perfusion, poor skin turgor) coexist, shock takes priority and hypotension and hypovolemia are immediately treated with normal saline and inotropic support along standard lines. Solutions that contain more than 50% “free water” (e.g., 5% Dextrose in water) should not be administered, except in small volumes when they are used to dissolve antibiotics.

I. ICP elevation is maximal in the initial 48 hours. It must be reduced to maintain cerebral perfusion and prevent cerebral infarction. In an emergency situation, elevate the head end by 30° to improve venous drainage from the brain and reduce the ICP. In raised ICP head end should be elevated but when herniation is suspected, head end should be lowered.

- (a) Prevent flexion of neck and any possible obstruction to jugular venous outflow (caused by turning of the head to a side).

- (b) Mannitol is an osmotic diuretic, Osmotic diuretics must be used in minimum necessary doses for the minimum necessary period only. Mannitol infusion loading dose is 5 ml/kg (1g/kg) of 20 % Mannitol, to be given IV rapidly over less than 20 minutes, followed by 1.25 ml/kg (0.25 g/kg) every 6-12 hours to treat persistent ICP elevation. Response to mannitol depends upon intracranial pressure, dose given over the previous 3 hours (better effect with lesser doses), and rate of administration. Rapid administration is more effective in reducing intracranial pressure (ICP) for a shorter duration, where as a slower infusion rate reduces the ICP to a lesser degree, but for a longer duration. Mannitol and glycerol slowly cross the blood brain barrier and on reaching a significant concentration after a few days result in water entering the brain from the vascular compartment due to osmotic pressure gradient. This is called rebound phenomenon. To delay this mannitol must be used at a dose of only 0.25 g/kg and not higher doses. It must not be used if serum Osmolality exceeds 300 mOsm/l since renal tubular damage with consequent renal failure results at a serum osmolality of 330 mOsm/l. Chronic continuous therapy must be avoided as the brain adapts to the sustained hyperosmolality of plasma with an increase in intracellular free amino acids, which contribute to the “idiogenic” osmoles that appear in the brain in its adaptation to hyperosmolality. Mannitol is contraindicated in congestive cardiac failure, renal failure and pulmonary edema.
- (c) Give Mannitol for the first three days followed by oral glycerol (either orally or through nasogastric tube) for a few days and then taper it off over the next few days. Glycerol 0.5 ml/Kg diluted in twice the volume of water or fruit juice 3 times daily may be used if the child can take orally or through Ryle’s tube.
- (d) The loop diuretic frusemide alone causes a slow reduction in ICP but when combined with Mannitol, the fall in ICP is rapid and remains low for a considerably longer period than when either agent is used alone. Frusemide 1 mg/kg/dose every 12 hours
- (e) Urine output must be carefully monitored and replaced to avoid hypovolemia and hypotension.
- (f) Normalize temperature. The increased metabolic demand from hyperthermia increases cerebral blood flow (CBF), cerebral blood volume (CBV) and intracranial pressure (ICP). Increased CBV and ICP result in increased cerebral edema, reduced CBF and deterioration of the supply to demand ratio. Shivering (can occur during sponging) increases ICP by increasing pleural (intrathoracic pressure). This can be prevented by promethazine 1 mg/kg in 3 divided doses in a day.
- (g) Hyperventilation can be used to reduce the intracranial pressure immediately. Over enthusiastic hyperventilation causes reduction of cerebral blood flow and must be avoided. Long-term hyperventilation worsens the outcome by inducing oligemia in marginally perfused brain tissue.
- (h) Sedation: Restlessness and agitation require diazepam.
- (i) Control Seizures.
- (j) If ICP is uncontrolled short acting barbiturate narcosis may be useful.
- (k) If facilities are available, ICP monitoring should be instituted and maintained below 15 mm Hg.
- (l) CSF pressure can be presumed to have returned to normal if the patient is afebrile, awake and alert, without focal signs.

II. Seizures: Seizures occur in about one third cases and must be treated aggressively.

For the treatment of uncontrolled seizures give

Diazepam IV or PR or Lorazepam



Repeat Diazepam IV or PR or Lorazepam



Phenytoin IV or Phenobarbitone IV



Paralyze and Ventilate

Midazolam or propofol infusion

(a) IV Diazepam 0.1 - 0.3 mg/Kg in 1-5 minutes.
The dose may be repeated in 5 - 20 minutes.

(b) Rectal Diazepam: Diazepam: Dose in general, is 0.5 mg/kg. Not recommended for children under 10 kg for technical reasons. For children of 10-15 kg body weight a dose of 5 mg should be used. For children of over 15 kg, 10 mg should be used. Diazepam rectal solution is available. Otherwise, oral syrup may be diluted 1:1 with ordinary water and used rectally.

(c) Lorazepam (0.05 mg/kg IV) is preferable to diazepam because of its longer half life.

(d) Midazolam: Midazolam, 0.15mg/kg, IV or IM.

(e) Considerations to a loading dose of phenytoin (20 mg/kg over 20 minutes) should be given if seizures continue. Phenytoin is preferable to phenobarbitone since the latter sedates the child and so interferes with the assessment of depth of coma. Phenobarbitone may be used if sedation also is desired along with seizure control. Phenytoin 10 - 20 mg /Kg over 10 - 20 minutes at a rate of less than 1 mg/Kg/ Minute. Repeat dose of 5 - 10 mg /Kg IV may be given after 1 hour, up to a maximum of 1000 mg. Never give IM, mix only in normal saline (never in dextrose) to a maximum concentration of 1mg in 1ml.

Then, flush the line with a few ml of normal saline since phenytoin irritates the veins due to its high pH (pH is 12). Give maintenance drug (if only diazepam was enough to stop Status Epilepticus), Phenytoin 5 - 10 mg/Kg may be given through a nasogastric tube.

(f) Suspension of Sodium Valproate (up to 60 mg/Kg) may be diluted 1:1 with water and administered as retention enema. It may be continued 30-60 mg/kg/day in 3 divided doses by either oral or rectal route. Intravenous valproate also may be infused in a dose of 20 mg/kg at 20 mg/min after failure of lorazepam and phenytoin regimen. The drug may be repeated whenever required.

(g) Anticonvulsants may be tapered off after a few days unless there is evidence of persistent seizure activity.

III. The basis of fluid restriction and current views: Animal studies of experimental meningitis and a human study from India suggests that fluid restriction may be harmful but the evidence is inconclusive⁴¹. In normovolemic patients fluids are empirically restricted to $\frac{2}{3}$ of maintenance or 800-1000 ml/m²/24 hours initially only till raised ICP and SIADH are excluded. Fluids may be given normally (1500-1700 ml/m²/24 hours) when serum sodium levels are normal.

Serum Sodium level alterations: Hyponatremia is the most common and important electrolyte disorder encountered in the neurologic intensive care unit. Hyponatremia can cause several types of CNS and circulatory disorders such as cerebral edema and increased intracranial pressure. SIADH, CSWS, and hyponatremia caused by the inappropriate use of hypotonic solutions, causing life threatening central nervous system (CNS) pathophysiology⁴². Iatrogenic causes, most conspicuously inadequate tonicity of intravenous fluids, should be promptly identified and removed

when possible. Bacterial meningitis is associated with increased total body water, low serum sodium and high ADH levels in more severe cases, SIADH. Current opinion is that the high ADH levels probably represent compensatory mechanisms to maintain cerebral perfusion in the presence of cerebral edema.

Cerebral salt wasting (CSW) syndrome is far less well-known than SIADH and also different from SIADH in diagnosis and treatment. Fig. 1 summarizes the current understanding of SIADH and CSWS.

Treatment of hyponatremia depends on the clinical manifestations. If it is acute in onset and is causing neurological dysfunction (serum sodium <120 mEq/L with CNS symptoms) then hypertonic saline is justified to correct it⁴³. Central pontine myelinolysis (clinically presents as locked-in syndrome) may occur from osmotically induced demyelination due to overly rapid correction of serum sodium and hypoxic-anoxic episodes during hyponatremia may contribute to the demyelination. In long standing hyponatremia (Low Sodium without any CNS abnormalities),

correction must be done slowly as mentioned above as by this time the brain generates “free osmoles”.

IV. Fever: Paracetamol, salicylates or tepid water bath may be used.

V. Treatment of predisposing factors: Parameningeal infection, systemic foci of infection or CSF leak etc require specific management.

VI. Waterhouse-Friderichsen syndrome: Emergency treatment with replacement doses of corticosteroids is warranted.

VII. Nursing Care: The nursing care is as important as medical care and is to prioritize Airway, Breathing and Circulation, accompanied by a rapid assessment of conscious level using the AVPU scale (Is the patient Awake, responding to Voice, responding to Pain or Unresponsive) and management of the unconscious child. Urinary catheterization in all unconscious children is a must. If not done, bladder distension makes the child restless. This restlessness will not respond to sedatives.

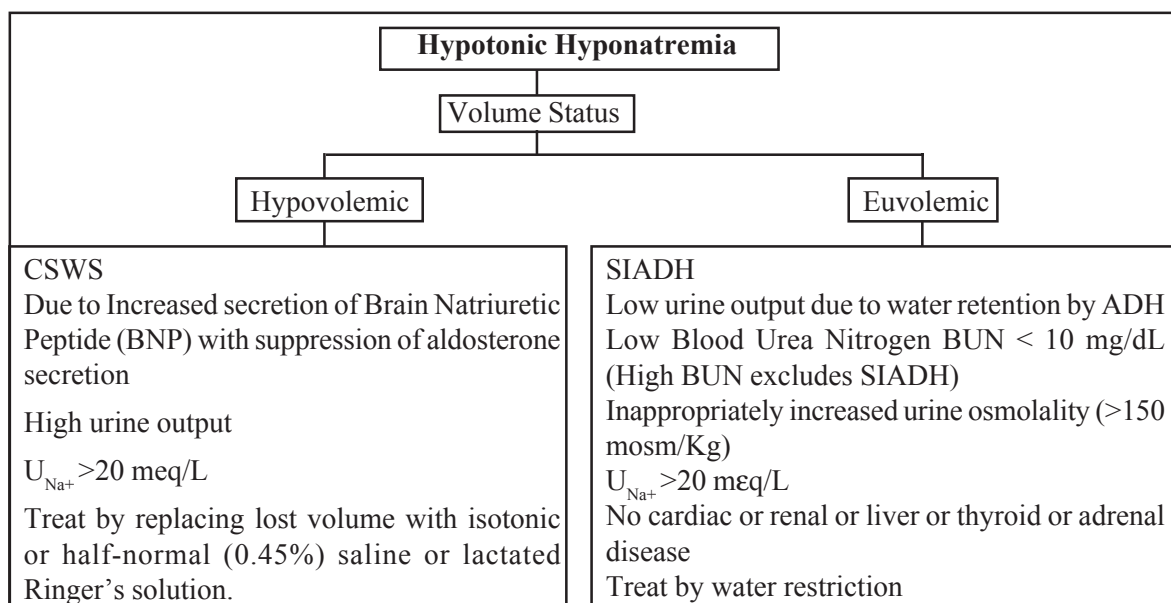


Fig. 1 SIADH and CSWS

Intermittent clamping of Catheter must be done to maintain bladder tone. Catheter may be removed when the child regains consciousness.

Complications: About 83% of appropriately treated children will have an uncomplicated recovery. The effects of bacterial meningitis vary according to the specific bacterial cause and the degree of impaired consciousness at presentation. Case-fatality rates and serious complications from meningitis caused by *S pneumoniae* infection have been reported to be as high as 40%. Mortality rates are usually lower in patients with meningitis caused by *N meningitidis* (5% to 10%) or *H influenzae* type b (3% to 6%).

Neurological complications: Seizures are discussed above.

Raised ICT may cause herniation at the incisura or foramen magnum leading to sudden respiratory arrest, sudden death or persistent vegetative state. Uncal herniation and sub falcial herniation can also occur. Treat immediately to prevent worsening of herniation.

Subdural effusion is common in infants⁴⁴ and is revealed by transillumination of skull or CT scan. It is seen in about 50% of young children with *H. influenzae* meningitis and is asymptomatic in 90% of them. They usually resolve spontaneously. Aspiration is indicated only if neurological deficits appear (raised ICP, progressive mass effect or altered sensorium). Persistent fever in children with subdural effusion due to *H.influenzae*, meningococcus or pneumococcus, is not an indication for drainage or laboratory testing since they are sterilized with standard treatment itself. Slowly waning fever in an otherwise uncomplicated recovery may be followed-up clinically. Aspiration of fluid may be necessary for demonstration of sterilization or for relief of raised intracranial tension.

Subdural empyema: It requires repeated aspirations using "Z" technique

Hydrocephalus: Communicating Hydrocephalus. Total obstruction is a medical emergency and presents with coma, Babinsky signs and paralysis of upward gaze.

Other complications include Ventriculitis, Cranial Nerve palsies, III, VI, VII and VIII cranial nerve dysfunction and quadriplegia.

Systemic Complications: SIADH, Hyponatremia and Waterhouse-Friderichsen syndrome are discussed above.

Shock: Septic shock is seen in meningococcal and Pneumococcal infections. Antibiotics may aggravate shock due to allergy/side effect. Hypovolemia may also cause shock.

Persistent fever (fever persisting after 10 days of antibiotics) is due to secondary bacterial infection / intercurrent viral infection / thrombophlebitis / drug reaction.

Recurrence of fever: Predisposing factors for acquisition of nosocomial meningitis include previous treatment with broad-spectrum antibiotics (68%) and total parenteral nutrition (32%)⁴⁵. Bacterial dissemination or immune complex deposition causes pneumonia or arthritis or pericarditis.

Anemia is due to hemolysis or bone marrow suppression. Acidosis, purpura fulminans, hypoglycemia, hypocalcemia and neurogenic pulmonary edema may occur. Adult Respiratory Distress Syndrome ("shock lung") is due to microcirculatory failure and causes severe hypoxemia and refractory pulmonary edema.

Endotoxemia and severe hypotension initiate coagulation cascade resulting in Disseminated Intravascular Coagulation.

Spinal cord infarction: The etiology is multifactorial, but vascular mechanisms and coagulation abnormalities play an important role.

Epidural hemorrhage and spinal abscess should be considered in the differential diagnosis⁴⁶.

Sequelae: Though significant improvement occurs due to neuronal plasticity, proper medical management, developmental and occupational therapy, excessive cytokine-induced inflammation continues after the CSF has been sterilized and is partly responsible for the sequelae. Sequelae reflect complications and are seen in 10-20% of survivors. Axonal pathology contributes significantly to neurologic sequelae after bacterial meningitis⁴⁷.

Sensorineural hearing loss occurs in about 10-47% of survivors⁴⁸. Because of compliance problems with outpatient audiological assessment and because early identification and expedient amplification lead to better academic and language outcomes, routine inpatient audiological screening of postmeningitic children is advocated. All recovered cases must be screened for this.

Hydrocephalus occurs in <5% and can present years later as CSF absorption and circulation are disrupted as meningeal adhesions mature. Other sequelae are epilepsy (4.2%), mental retardation (4.2%), visual impairment, behavioral problems, motor deficits 3.5%, learning disabilities, syringomyelia and focal neurologic problems (e.g., spasticity, paresis, ataxia, cortical blindness).

The mortality rate for pyogenic meningitis varies according to organism (high with pneumococcus 10-30%), age (high in infants), underlying predisposing factor (Listeria, 9% with no immune defect to about 60% with immune suppression) and clinical status when treatment is started (the later the initiation of therapy, the worse the mortality rate).

Factors associated most frequently with poor outcome include absence of respiratory infection, high cerebrospinal fluid protein, and

compromised cranial nerves. Early identification of major risk groups is important to adopt measures to improve prognosis⁴⁹.

Conclusion

Despite advances in antibacterial therapy, bacterial meningitis in childhood is associated with morbidity rates of about 20% and mortality rates of about 5% even in developed countries⁵⁰. The disease is of special concern because consequences are potentially devastating and because isolates with reduced susceptibility to penicillin are found in increasing and alarming numbers. Hib is the most predominant cause of meningitis in young Bangladeshi children. Resistance to ampicillin and chloramphenicol and the high cost of third-generation cephalosporin highlight the importance of disease prevention through vaccination against Hib⁵¹. An effective vaccination program against *Streptococcus pneumoniae* and *H. influenzae* type b should reduce the prevalence of sensorineural hearing loss due to bacterial meningitis in India⁵².

Points to remember

1. *High index of suspicion of Pyogenic meningitis and educated guess in initial selection of antibiotics before culture results are available is useful in reducing the morbidity and mortality.*
2. *Presence of papilledema has important implications.*
3. *Nursing care is as important as medical care.*

References

1. Sahai S, Mahadevan S, Srinivasan S, Kanungo R. Childhood Bacterial Meningitis in Pondicherry, South India. *Indian J Pediatr* 2001; 68:839-841.
2. Martin M, Casellas JM, Madhi SA, et al. Impact of *Haemophilus influenzae* Type b Conjugate Vaccine in South Africa and Argentina. *Pediatr Infect Dis J* 2004 ; 23(9):842-847.

3. Cheng BC, Chang WN, Lu CH, et al. Bacterial meningitis in hemodialyzed patients. *J Nephrol*. 2004 ;17(2):236-241.
4. Callanan V, Poje C. Cochlear implantation and meningitis. *Int J Pediatr Otorhinolaryngol*. 2004;68(5):545-550.
5. Ginsberg L. Difficult and recurrent meningitis. *J Neurol Neurosurg Psychiatry*. 2004;75 Suppl 1:i16-21.
6. Hamilton D, Harris MD, Foweraker J, Gresham GA. Waterhouse-Friderichsen syndrome as a result of non-meningococcal infection. *J Clin Pathol* 2004;57(2):208-209
7. Chang CJ, Chang HW, Chang WN, et al. Seizures complicating infantile and childhood bacterial meningitis. *Pediatr Neurol*. 2004; 31(3):165-171.
8. Mukherjee S, Sharief N. Bacterial meningitis presenting as acute torticollis. *Acta Paediatr*. 2004; 93(7):1005-1006.
9. Pandian JD, Sarada C, Radhakrishnan VV, Kishore A. Iatrogenic meningitis after lumbar puncture-a preventable health hazard. *J Hosp Infect* 2004; 56(2):119-124.
10. Givens TG, Paul RI, Bothner JP, Hardwick WE, Jr., Walsh-Kelly CM. Cerebrospinal fluid glucose and protein in disposition and treatment decisions. *Acad Emerg Med* 2000; 7(3):298-302.
11. Eisenhut M, Meehan T, Batchelor L. Cerebrospinal fluid glucose levels and sensorineural hearing loss in bacterial meningitis. *Infection* 2003; 31(4):247-250.
12. Lipton JD, Schafermeyer RW. Evolving concepts in pediatric bacterial meningitis—Part I: Pathophysiology and diagnosis. *Ann Emerg Med* 1993; 22(10):1602-1615.
13. Pemde HK, Harish K, Thawrani YP, Shrivastava S, Belapurkar KM. C-reactive protein in childhood meningitides. *Indian J Pediatr* 1996; 63(1):73-77.
14. Beratis NG, Eliopoulou MI, Syrogiannopoulos GA. Beta-glucuronidase in the diagnosis of bacterial meningitis and response to treatment. *Acta Paediatr* 2003; 92(11):1272-1276.
15. Nigrovic LE, Kuppermann N, McAdam AJ, Malley R. Cerebrospinal latex agglutination fails to contribute to the microbiologic diagnosis of pretreated children with meningitis. *Pediatr Infect Dis J* 2004;23(8):786-788.
16. Kanungo R, Bhaskar M, Kumar A, Badrinath S, Rajalakshmi B. Detection of pneumolysin in cerebrospinal fluid for rapid diagnosis of Pneumococcal meningitis. *Indian J Med Res* 2004;119(2):75-78.
17. Smith K, Diggle MA, Clarke SC. Automation of a fluorescence-based multiplex PCR for the laboratory confirmation of common bacterial pathogens. *J Med Microbiol*. 2004;53 (Pt 2):115-117.
18. Schuurman T, de Boer RF, Kooistra-Smid AM, van Zwet AA. Prospective study of use of PCR amplification and sequencing of 16S ribosomal DNA from cerebrospinal fluid for diagnosis of bacterial meningitis in a clinical setting. *J Clin Microbiol* 2004; 42(2):734-740.
19. Parmar RC, Warke S, Sira P, Kamat JR. Rapid diagnosis of meningitis using reagent strips. *Indian J Med Sci*. 2004;58(2):62-66.
20. Tuncer O, Caksen H, Arslan S, et al. Cranial computed tomography in purulent meningitis of childhood. *Int J Neurosci* 2004;114(2):167-174.
21. Polk DB, Steele RW. Bacterial meningitis presenting with normal cerebrospinal fluid. *Pediatr Infect Dis J* 1987; 6(11):1040-1042.
22. Wong M, Schlaggar BL, Landt M. Postictal cerebrospinal fluid abnormalities in children. *J Pediatr* 2001;138(3):373-377.
23. Bonsu BK, Harper MB. Fever interval before diagnosis, prior antibiotic treatment, and clinical outcome for young children with bacterial meningitis. *Clin Infect Dis* 2001;32(4):566-572.
24. Sinner SW, Tunkel AR. Antimicrobial agents in the treatment of bacterial meningitis. *Infect Dis Clin North Am* 2004 Sep;18(3):581-602.
25. Stahl JP. [Antibiotic treatment of bacterial meningitis] [Article in French]. *Rev Prat* 2004; 54(9):963-967

26. Prasad K, Singhal T, Jain N, Gupta PK. Third generation cephalosporins versus conventional antibiotics for treating acute bacterial meningitis. *Cochrane Database Syst Rev* 2004; (2): CD001832.
27. Fuller DG, Duke T, Shann F, Curtis N. Antibiotic treatment for bacterial meningitis in children in developing countries. *Ann Trop Paediatr*. 2003; 23(4):233-253.
28. Balbi HJ. Chloramphenicol: a review. *Pediatr Rev* 2004; 25(8):284-288.
29. Hitomi S, Ohto T, Okamoto M, Nishimura Y, Iwasaki N, Matsui A. A case of listerial meningitis treated with a regimen containing panipenem-betamipron. *J Infect Chemother* 2004 ; 10(4):242-544.
30. Lee NY, Song JH, Kim S, Peck KR, Ahn KM, Lee, et al. Carriage of antibiotic resistant pneumococci among Asian children – A multinational surveillance by the Asian network for surveillance of resistant pathogens (ANSORP). *Clin Infect Dis* 2001;32:1463-1469.
31. Cottagnoud PH, Tauber MG. New therapies for pneumococcal meningitis. *Expert Opin Investig Drugs*. 2004 ; 13(4):393-401.
32. Hasegawa K, Chiba N, Kobayashi R, et al. Rapidly increasing prevalence of beta-lactamase-nonproducing, ampicillin-resistant *Haemophilus influenzae* type b in patients with meningitis. *Antimicrob Agents Chemother* 2004; 48(5):1509-1514.
33. Sudo F, Nakamura A, Hoshino T, Ishiwada N, Kohno Y. [Successful treatment of beta-lactamase-negative ampicillin-resistant *Haemophilus influenzae* type b meningitis with high-dose ceftriaxone administration] *Kansenshogaku Zasshi* 2004;78(7):604-608.
34. Pistella E, Campanile F, Bongiorno D, et al. Successful treatment of disseminated cerebritis complicating methicillin-resistant *Staphylococcus aureus* Endocarditis unresponsive to vancomycin therapy with linezolid. *Scand J Infect Dis* 2004;36(3):222-225.
35. Krueger WA, Kottler B, Will BE, Heininger A, Guggenberger H, Unertl KE. Treatment of meningitis due to methicillin-resistant *Staphylococcus epidermidis* with linezolid. *J Clin Microbiol* 2004; 42(2):929-932.
36. Lalueza Broto MP, Lopez Martinez R, Dominguez Cenozo L, Garnacho de Vega A. [Treatment of multiresistant *Staphylococcus epidermidis* meningitis with linezolid] [Article in Spanish]. *Med Clin (Barc)* 2004; 21;122(6):238-239.
37. Corpus KA, Weber KB, Zimmerman CR. Intrathecal amikacin for the treatment of pseudomonal meningitis. *Ann Pharmacother* 2004;38(6):992-995.
38. Chaudhuri A. Adjunctive dexamethasone treatment in acute bacterial meningitis. *Lancet Neurol* 2004; 3(1):54-62.
39. Gupta S, Tuladhar AB. Does early administration of dexamethasone improve neurological outcome in children with meningococcal meningitis? *Arch Dis Child* 2004; 89(1):82-83.
40. Singhi SC, Khetarpal R, Baranwal AK, Singhi PD. Intensive care needs of children with acute bacterial meningitis: a developing country perspective. *Ann Trop Paediatr*. 2004 ;24(2):133-140.
41. Singhi SC, Singhi B, Srinivas B, Narakesri HP, Ganguli NK, Sialy Rea. Fluid restriction does not improve the outcome of acute meningitis. *Pediatr Infect Dis J* 1995; 14:495-503.
42. Miyasaka K, Shimizu N, Kojima J. Recent trends in pediatric fluid therapy. *Exp Clin Pharmacol* 2004; 26(4):287-294.
43. Rabinstein AA, Wijdicks EF. Hyponatremia in critically ill neurological patients. *Neurologist*. 2003; 9(6):290-300.
44. Ranjini EK, Agarwal I, Kirubakaran C. Pneumococcal subdural empyema in young infants. *Indian Pediatr*. 2004; 41(5):505-508.
45. Lin PC, Chiu NC, Li WC, et al. Characteristics of nosocomial bacterial meningitis in children. *J Microbiol Immunol Infect*. 2004; 37(1):35-38.
46. Van Egeraat SC, Van Munster ET, Bodewes HW, Van Der Hoeven JG. Spinal cord

- infarction as a severe complication of meningococcal meningitis. *Eur J Intern Med* 2003; 14(6):383-385.
47. Nau R, Gerber J, Bunkowski S, Bruck W. Axonal injury, a neglected cause of CNS damage in bacterial meningitis *Neurology*. 2004; 10;62(3):509-511.
 48. Damodaran A, Aneja S, Malhotra VL, Bais AS, Ahuja B, Taluja V. Sensorineural hearing loss following Acute Bacterial Meningitis- A Prospective evaluation. *Indian Pediatr* 1996;33:763-766.
 49. Lucena R, Fonseca N, Nunes L, Cardoso A, Goes J, Correia MC, Cardoso E, Queiros F, Anjos LP, Vila-Nova C, Melo A. Intra-hospital lethality among infants with pyogenic meningitis. *Pediatr Neurol* 2005; 32(3):180-183.
 50. Baraff LJ, Lee SI and Schriger DL. Outcomes of bacterial meningitis in children: a meta-analysis. *Pediatr Infect Dis J* 1993; 12:389-394.
 51. Saha SK, Baqui AH, Darmstadt GL, Ruhulamin M, Hanif M, El Arifeen S, Oishi K, Santosham M, Nagatake T, Black RE. Invasive *Haemophilus influenzae* type B diseases in Bangladesh, with increased resistance to antibiotics. *J Pediatr* 2005;146(2):227-233.
 52. Cherukupally SR, Eavey R. Vaccine-preventable pediatric postmeningitic sensorineural hearing loss in southern India. *Otolaryngol Head Neck Surg* 2004;130(3): 339-343.

NEWS AND NOTES

Pediatric Emergency Medicine Course

Venue: Mumbai.

Date: 18th and 19th June 2005

Address for Correspondence: Dr. Anand Shandilya, Ph: (022) 28320073, Dr. Deepak Ugra, Mobile: 98201 47923, Email: deepakugra@hotmail.com, shandilya3@hotmail.com

Meningococcal outbreak - Advice to the traveling child

Meningococcal vaccine bivalent (serogroups A,C) or quadrivalent (A,C,Y,W135), given subcutaneously, is recommended for high risk children older than two years. The vaccine is ineffective against serogroup A in infants under 3 months of age and maybe only partially effective against this serogroup in children 3 to 11 months of age. Children younger than 2 years of age are not protected against the other serogroups. Vaccination should be done at least seven to ten days prior to travel to the place of outbreak. If vaccine has been given within the preceeding 3 years there is no need to vaccinate again. But vaccination may be used as an adjunct with chemoprophylaxis for exposed contacts.

Contact chemoprophylaxis is recommended, for all close contacts of patients with meningococcal infection regardless of age or immunization status, as soon as possible after identification or contact with patient's oral secretions during 7 days before onset of illness. *Rifampicin* - 5 mg/kg/dose for infants less than 1 month and 10 mg/kg/dose (maximum 600 mg) for all other ages, every 12 hours for 2 days. *Ceftriaxone* - 125 mg single dose, IM for children less than 12 years and 250 mg, IM for those more than 12 years. *Ciprofloxacin* - orally as a single dose for those 18 years or above.

RADIOLOGIST TALKS TO YOU

NEONATAL JAUNDICE

*** Vijayalakshmi G**

**** Natarajan B**

***** Ramalingam A**

Physiological jaundice is a common event encountered both in full term and preterm infants. But when there is a suspicion that it is pathological, further evaluation is necessary. In the evaluation of NCS a good clinical assessment, laboratory and radiological work up is required to differentiate the medical and surgical causes. Various imaging modalities may be helpful in the investigative protocol.

The initial imaging modality is ultrasonography. The single important feature is the identification of a normal gall bladder (GB), which more or less rules out biliary atresia. Biliary atresia is characterized by the absence of the gall bladder. The finding of a normal-sized gall bladder usually denotes neonatal hepatitis. This is a simple working rule, which helps in differentiating between surgical and medical neonatal jaundice. The exception to this is when atresia involves the common bile duct (CBD) distal to the insertion of the cystic duct. This is extremely rare but a normal GB may be seen in this kind of biliary atresia. Confirmation is by operative cholangiography.

Another feature in biliary atresia, is the presence of a remnant of the CBD seen as a white dot or triangle at the porta hepatis above the bifurcation of the portal vein (Fig. 1). This is seen in most cases of biliary atresia and is called the triangular cord sign. This white dot is not seen in biliary atresia associated with polysplenia syndromes, situs anomalies and complex cardiac disease.

Although the finding of a normal-sized gallbladder usually implies neonatal hepatitis, a small (less than 1.5 cm) gall bladder is non-specific and may be seen with either hepatitis or biliary atresia. Change in gall bladder size after a milk feeding suggests patency of the common hepatic and common bile ducts and is seen in neonatal hepatitis.

In infants with poor hepatobiliary excretion, the gall bladder is not filled and sonographic differentiation between neonatal hepatitis and biliary atresia may be difficult. Thus, in doubtful situations, hepatobiliary scintigraphy or operative cholangiography should be performed to assess whether there is normal bile excretion into the small intestines.

This brings us to the next imaging modality, which is hepatobiliary nuclear scan. In this study, a radiopharmaceutical agent such as iminodiacetic acid is given intravenously. This radionuclide agent is extracted by the liver and excreted through the biliary radicals and the CBD into the duodenum. Therefore, the presence of activity in the small bowel rules out biliary atresia. In biliary atresia the gall bladder may not be visualised and no intestinal activity seen in the delayed film (>22 hrs) (Fig. 2). This is helpful

* Addl Professor, Dept. of Radiology
Chengelpet Medical College and Hospital.

** Lecturer

*** Reader
Dept. of Radiology
ICH & HC., Egmore, Chennai.

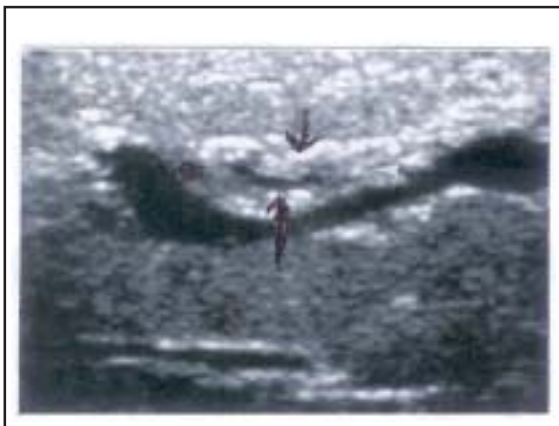

Fig. 1 A highly magnified view of the porta-hepatitis. The triangular cord sign.



Fig. 3 Normal operative cholangiogram (D – duodenum)




Fig. 5 MR cholangiography showing the normal GB, CBD and the right and left (L) hepatic ducts.

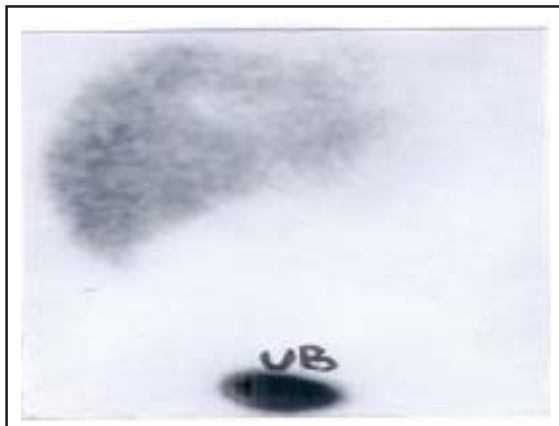

Fig. 2 Hepatobiliary scan. There is no opacification of the GB in a case of biliary atresia. Note the tracer in the urinary bladder.

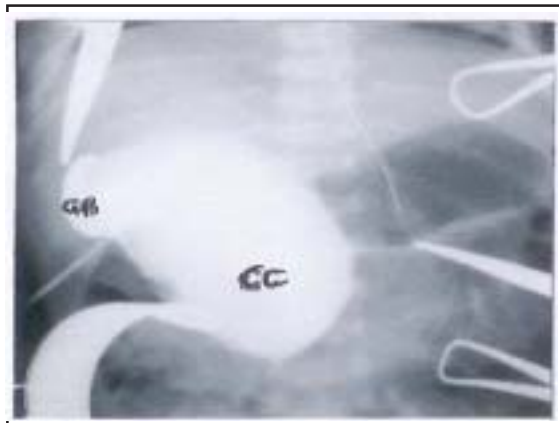

Fig. 4 Operative cholangiogram. Choledochal cyst (cc) with no contrast in the duodenum.

in infants less than three months of age with features of NCS and adequate hepatic function. In children with prolonged cholestasis beyond this age hepatocellular function is too poor for tracer uptake and it is impossible to differentiate between neonatal hepatitis and biliary atresia. Hence hepato-biliary scintigraphy will not be helpful when liver function has deteriorated.

The final confirmative and diagnostic test is the operative cholangiogram. This test as its name suggests is invasive. The gall bladder is

identified by laparotomy or laparoscopy. The contrast is injected into the gall bladder. If there is no obstruction, the contrast flows through the CBD into the duodenum. Tilting of the patient appropriately will also opacify the proximal hepatic ducts (Fig.3). Thus the operative cholangiogram gives a clear picture of the pathology (Fig 4). At the Institute of Child Health, Chennai, this modality is frequently used after the initial ultrasound evaluation.

MR cholangiopancreatography (Fig 5) may also provide useful information for evaluating the patency of biliary ducts. This test requires sedation of the child as movement of the child results in artifacts. MR Cholangiography uses signal from the bile within the ducts to allow visualization of the biliary system. Therefore, MR imaging is best used to evaluate the extrahepatic biliary ductal system. If the CBD is

visualized biliary atresia can be excluded.

The primary goal in imaging a child with neonatal jaundice is to decide whether operative intervention is required or not. Early diagnosis of biliary atresia is essential as the best results are achieved in infants who are operated on or before 60 days of age. Very poor results are seen when surgery is done after 90 days of age because of the development of cirrhosis.

With this we conclude with imaging of jaundice in children. Imaging in an organized manner will facilitate prompt treatment. Start with ultrasound which may provide the clue and no other investigations may be necessary. In certain cases, as in biliary atresia or when the GB is very much contracted, correlative studies like nuclear scan or cholangiography may be required.

NEWS AND NOTES

ITP STUDY GROUP

At the recently held First National Conference on Idiopathic Thrombocytopenic Purpura, it was decided to form ITP Study Group with a view to study the natural history of the disease in India and also to see the commonly prevailing practice in treating this disease. Based on the information collected in this study, recommendations can be made about the management of ITP in India including a possible role of alternative forms of therapy.

Those who are interested in joining the study group should contact Dr.BC Mehta at (labmed@ghrc-bk.org). It is necessary that those who wish to join the group have easy access to internet. All communications of the study group will be through e-mail and web. Members will have access to the data/information on web.

Indian Academy of Pediatrics - Tamilnadu State Chapter

Recent Advances in Pediatrics

Date: 12th June 2005

Venue: Triple Helix Auditorium, Adyar, Chennai.

Update on Neonatal Care

Date: 10th July 2005

Venue: Triple Helix Auditorium, Adyar, Chennai.

For further details contact: Dr.D.Gunasingh, Secretary, IAP-TNSC, IAP House, 56 (Old No.33), Halls Road, Halls Towers, F Block, Ground Floor, Egmore, Chennai – 600 008. Phone Off: (044) 28191524, Res: 26531692, Mobile: 09444015854. Email: iaptnsc@vsnl.net.in; drgunasingh@vsnl.net

| |
|-------------------|
| CASE STUDY |
|-------------------|

CONGENITAL ESOPHAGEAL STENOSIS

* **Malathi Sathiyasekaran**

** **Lalitha Janakiraman**

*** **Shivbalan So**

**** **Deenadayalan M**

Abstract: Congenital esophageal stenosis (CES) is an uncommon cause of dysphagia in children. We are reporting 2 children with CES who presented with food impaction.

Keywords: Congenital esophageal stenosis, children, food impaction

Congenital esophageal stenosis (CES) is an uncommon cause of dysphagia in children. Children with CES can present as failure to thrive, recurrent vomiting or food impaction. We are reporting 2 children with CES who presented with food impaction.

Case 1

A 2 year old male child was brought with history of acute dysphagia and drooling of saliva for 48 hours. There was no history of choking, cough, stridor, hoarseness of voice or breathlessness. He had no previous history of dysphagia but generally preferred liquid and semisolid diet. There was no history of foreign body ingestion. However the mother had seen the elder sibling eating grapes on the day of onset of symptoms. On examination he was conscious,

afebrile and dehydrated and kept pointing to his suprasternal notch. His throat and systemic examination were normal. His chest skiagram was normal. He was rehydrated with intravenous fluids and an emergency upper GI endoscopy was done. Endoscopy revealed a spherical, shiny, smooth, green grape in the mid esophagus (17 cms from incisor teeth) (Fig.1) moving like a ball valve with a stricture of about 5 mm in diameter distal to the fruit. The fruit was removed and endoscopic dilatation done under fluoroscopy using Savary Gilliard dilators. Child had no complication and showed remarkable improvement in his eating. This child is on regular follow up for the last 2 years and he required a second dilatation 7 months after the first procedure.

Case 2

A 1 year 8 month old boy was brought with one day history of dysphagia for both solids and liquids following ingestion of "Zizyphus" (Indian plum or berry). He had no respiratory symptoms. He was diagnosed earlier as a picky eater preferring only liquid and semisolid diet. There was no history of surgery or corrosive ingestion. On examination he was anxious and dehydrated with drooling of saliva. After resuscitation an emergency upper G.I endoscopy was performed which revealed an impacted plum in the mid esophagus (17 cms from incisor teeth) with an underlying esophageal stricture. The "plum" was removed and the stricture dilated using Savary Gilliard dilators. Post dilatation endoscopy was done in both the children and the esophagus beyond the stricture up to the second part of duodenum was normal. There was no hiatus hernia or evidence of reflux esophagitis.

* Consultant Pediatric Gastroenterologist

** Consultant Pediatrician

*** Junior consultant in Pediatrics

**** Registrar in Pediatrics

Kanchi Kamakoti CHILDS Trust Hospital
Chennai 600 034.

Discussion

Esophageal stenosis in children can be either congenital (5%) or acquired (95%). Congenital esophageal stenosis is of 3 types membranous diaphragm, fibromuscular stenosis and stricture due to ectopic tracheo-bronchial tissue containing cartilage¹. Frey and Duschel reported the latter in 1936². CES commonly affects the middle and distal third of esophagus. They are usually asymptomatic in the neonatal period. Later the children may present with vomiting of undigested food, regurgitation, food impaction, dysphagia and failure to thrive. CES involving the upper third of esophagus is very rare and presents with stridor and recurrent respiratory infections¹. CES may be associated with esophageal atresia, tracheo-esophageal fistula or other developmental anomalies of the gastrointestinal tract^{1,3}.

Barium swallow and upper GI scopy confirms the diagnosis. The membranous type can be distinguished easily. The other two types appear similar but response to endoscopic dilatation is excellent in the fibromuscular type compared to the ectopic tracheobronchial type that is usually seen in the lower end of the oesophagus. The management of CES prior to the endoscopic era was surgical resection and anastomosis, the advantage of this procedure being the possibility of good histopathological examination. Nowadays endoscopic dilatation over the guide wire using tapered polyvinyl bougies or balloons is an accepted method of management^{1,2,4}. If the CES is due to ectopic tissue with cartilage as a component, the therapeutic response is not satisfactory and surgery is advocated. Since these two children responded to endoscopic dilatation fibromuscular type is a possibility.

Foreign body in the aero digestive tract is a common problem in children. In the normal oesophagus the common site of impaction is the

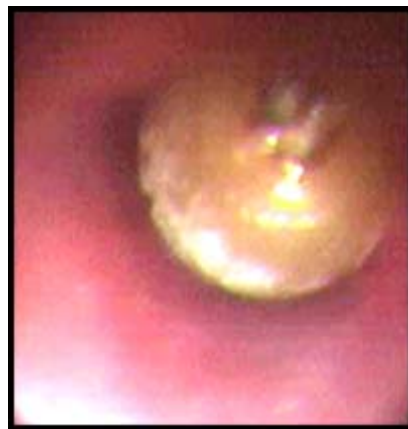

Fig 1. Upper GI scopy shows a whole green grape in the mid esophagus

cricothyroid junction and rarely at other sites. It is a dictum that all FB in the esophagus should be removed as an emergency. After its removal unlike bronchial foreign body it is essential to exclude underlying strictures. This report highlights the importance of excluding underlying anatomical abnormalities in children presenting with esophageal foreign body.

References

1. Congenital esophageal stenosis. Pediatric surgery update Vol 17 (4); 2001. Available from: URL: <http://home.coqui.net/titolugo/PSU17.htm#1741> Accessed on July 5,2004.
2. Shorter NA, Mooney DP, Vaccaro TJ, Sargent SK. balloon dilation of congenital esophageal stenoses associated with esophageal atresia. J Pediatr Surg 2000; 35(12):1742-1745.
3. Ibrahim NB, Sandry RJ. oesophageal stenosis caused by tracheobronchial structures in the oesophageal wall. Thorax 1981; 36(6): 465-468.
4. Ramesh JC, Ramanujam TM, Jayaram G. Congenital esophageal stenosis: report of three cases, literature review, and a proposed classification. Pediatr Surg Int 2001; 17(2):188-192.

CASE STUDY**FIBRODYSPLASIA OSSIFICANS PROGRESSIVA**

* **Arulprakash**

** **Rakesh Kain**

*** **Maya Chansoria**

Abstract: *Fibrodysplasia ossificans progressiva (FOP) is a rare deforming disease, affecting the skeleton and associated with progressive enchondral ossification of the striated muscles. Swelling of the soft parts is rare and can be the initial manifestation. We report a classical case where initial swelling preceded the ossification and review of literature.*

Key words: *Fibrodysplasia ossificans progressiva (FOP), Myositis ossificans progressiva, Endochondral ossification.*

Fibrodysplasia ossificans progressiva is a dominantly inherited connective tissue disorder, in which defects in skeletal patterning are associated with progressive endochondral ossification of large striated muscles^{1,2}.

A 2 year old child born of a non-consanguineous marriage presented with multiple painful swellings over back mostly in the cervical and thoraco-lumbar region since 4 months of age. The swelling started in scalp region following minimal trauma. It subsided to a lesser extent in due course only to reappear in another site. On examination he had multiple swellings all over the back extending from the neck to thoraco-

lumbar region, which was firm in consistency and painful on palpation. He had bilateral hallux valgus malformation with overriding of big toe over the second. Initial laboratory investigations were otherwise normal. Skeletal radiographs showed ectopic calcification in the region of neck, shoulders and back. Biopsy of lesions showed myxoid fibrous tissue. Hence a diagnosis of fibrodysplasia ossificans progressiva was entertained.

Fibrodysplasia ossificans progressiva is an extremely rare and disabling condition of connective tissue differentiation characterized by congenital malformation of great toe with heterotopic calcification of ligaments, tendon, fascia and striated muscles. A point prevalence of one affected patient in every two million population has been observed. FOP occurs sporadically and is transmitted as dominant trait with variable expression and complete penetrance with no sexual, racial or ethnic predilection. Average age of onset is 5 years. The FOP gene has been recently mapped to human chromosome 4 q 27-31³. Bone morphogenetic protein-4 (BMP -4) a potent osteogenic morphogen is over expressed in lymphoblastic cells of FOP and is said to be involved in the pathogenesis. BMP-4 is responsible for formation and regeneration of skeletal and hematopoietic systems in vertebrates⁴. Defective regulation of endochondral osteogenesis is the main pathogenetic mechanism in FOP⁵. This disease presents in early life and it is gradually progressive. Associated malformations (90% of cases) considered essential for diagnosis include hypoplastic big toes, proximally placed phalanx, hallux valgus, syndactyly and short malformed

* Resident, Dept of Pediatrics

** Assistant Professor, Dept of Surgery,

*** Professor and Head, Dept of Pediatrics,
NSCB Medical College, Jabalpur, MP

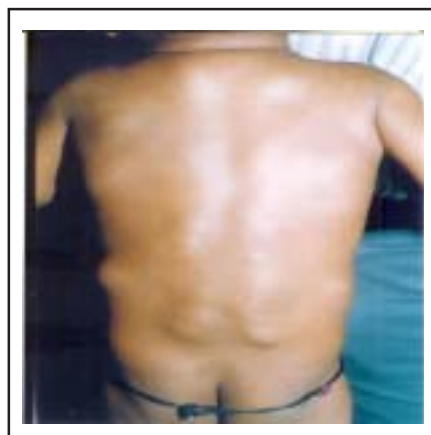

Fig. 1Two year old child showing multiple swelling in back

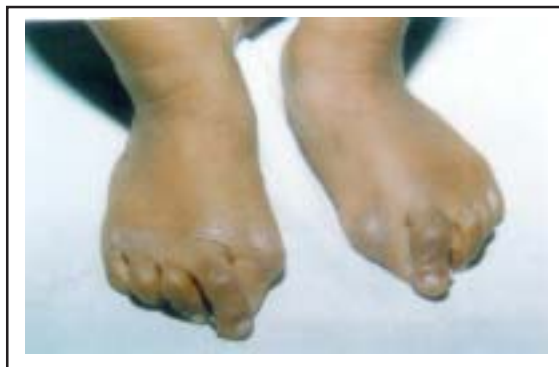

Fig. 2 Hallux valgus

thumbs. Awareness of the association clinches the diagnosis. The most common sites of heterotopic calcification are the neck, spine and shoulder girdle. The pattern of progress is from axial to appendicular, cranial to caudal and proximal to distal⁵. Lesions follow different stages on its progress; they are, stage of inflammation (pain, erythema, swelling, warmth and tenderness), intermediate lesion and a late irreversible ossified lesion⁶. Radiography shows ectopic calcifications. Trauma to deep muscles is a stimulus for ossification (e.g. immunization). Lesions must not be biopsied as it aggravates the process of calcification and the child must be protected from even most trivial trauma. Debilitating joint immobility due to ossification of almost all joints is the ultimate outcome on account of the progressive nature. Most of the patients are confined to wheel chair by third decade of life and often succumb to pulmonary complications in the fifth or sixth decade of life³. Extraocular, diaphragm, cardiac and smooth muscles are characteristically spared. Premature death can occur from respiratory failure due to thoracic cage involvement⁵. Till date there is no definite therapy to impede the progression of disease. Oral steroids and etidronate have some

encouraging results⁷. Etidronate has inhibitory effect on bone mineralization and has a potential to impair rapid ossification. Isotretinoin also inhibits differentiation of mesenchymal tissue into cartilage and bone. Despite therapy all the patients develop new ossifications.

References

1. Lutwak L. Myositis ossificans progressiva mineral, metabolic and radioactive calcium studies of the effect of hormones. *Am J Med* 1964; 37:269-293.
2. Smith DM, Russel RGG, Woods CG. Myositis ossificans progressiva clinical features of eight patients and their response to treatment. *J Bone Surg* 1976; 58:48-57.
3. Mahoubou S, Glauser DL, Shore EM, Kaplan FS. Fibrodysplasia ossificans progressiva. *Pediatr Radiol* 2001; 31:307-314.
4. Gannon FH, Kaplan FS, Olmsted E. Bone morphogenetic protein 2/4 in early fibromatous lesions of fibrodysplasia ossificans progressiva. *Hum Pathol* 1997; 28:339.
5. Herring JA. Orthopedic related syndromes. In: Ed Herring JA. *Tachdjian's Pediatric Orthopedics*, 3rd ed, Ed Herrang JA, Philadelphia, WB Saunders company, 2002; pp.1632-1639.

6. Kaplan FS, Tabas JA, Gannon FH. The histopathology of fibrodysplasia ossificans progressiva: an endochondral process. J Bone Joint Surg 1993; 75-A: 220.
7. Bridges AJ, Hsu KC, Singh A: Fibrodysplasia (myositis) ossificans progressiva. Semin Arthritis Rheum 1994; 24: 155.

OBITUARY

DR. R.K. PURI

Dr. Ramesh K. Puri hailed from Hoshiarpur in Punjab. He was a graduate of the Patiala Medical College and a postgraduate in Pediatrics from JIPMER, Pondicherry. Prof. Puri began his teaching carrier as a faculty in the Department of Pediatrics at JIPMER, Pondicherry and later rose to the post of Professor and Head in the same institution. He joined the Department of Pediatrics at Maulana Azad Medical College (MAMC), New Delhi as its Head in February 1989 and retired from there as the Director Professor and Head in January 1995. The Department of Pediatrics at MAMC was modernized during his tenure. Prof. Puri also efficiently discharged additional important institutional responsibilities.

During an illustrious career that spanned four decades, Prof. Puri held many responsible positions and was respected as an academician and an astute clinician. He was the Editor-in-Chief of *Indian Pediatrics* from 1990-1994. During his tenure the publication scaled new heights and was adjudged as the best medical journal from India. He was the Organizing Secretary of the VIII Asian Congress of Pediatrics (ACP) held at New Delhi in February 1994. Under his dynamic stewardship the VIII ACP established a global precedent by not accepting any financial support from the Infant Milk Substitute industry, which received international acclaim. The conference was not only an academic success but also a financial accomplishment, with huge savings for the Indian Academy of Pediatrics. During his tenure at MAMC, he was the principal investigator of large community projects funded by the World Health Organization and the World Bank. He had several indexed research publications to his credit and also edited popular books. Dr. Puri was an eminent teacher who was dearly loved by his students. Other noteworthy virtues were his compassionate attitude, easy accessibility to all, and the ability to encourage junior colleagues to perform better. He could easily lower the anxiety level by taking of problems others on his shoulders and stating "do not worry, I am there!" ("*main hun na!*").

Consequent to his retirement from MAMC, he joined the Apollo Hospitals at Delhi as a Senior Consultant. At the time of his untimely death on January 21, 2005, at the age of 68 years, he was also the Academic Advisor to the Apollo Centre for Advanced Pediatrics and Editor-in-Chief of Apollo's Medical Journal. He is survived by his wife and son. His death has left a void in the pediatric fraternity that would be hard to fill.

NEWS AND NOTES

IX National Pediatric Hemato-Oncology Conference

Date: 22nd & 23rd October 2005.

Venue: Bilaspur (Chhattisgarh).

Address for Correspondence: Dr. Pradeep Sihare, Organizing Secretary, Children's Hospital, Nirala Nagar, Bilaspur (Chhattisgarh) – 495 001. Ph: 07752-225704, 224888. Email: ssihare@yahoo.com

| |
|--------------------|
| BOOK REVIEW |
|--------------------|

| | |
|-------------------|---|
| Name | Immunization in Clinical Practice |
| Editors | Naveen Thacker, Nitin K Shah |
| Review: | <p>Immunization is one of the important child health survival strategies. The pediatrician who was administering 3 or 4 vaccines and following a fairly straightforward immunization schedule two decades ago, is currently confronted with a multitude of vaccines and the problem of devising an appropriate immunization schedule for the children under his care. He has to know the epidemiology of vaccine preventable diseases where he practices, the efficacy of the vaccines and the affordability of parents before he decides on a set of vaccines for the individual child in consultation with parents. Immunization along with growth monitoring and counseling forms a major part of pediatric practice especially in urban and semi urban areas. It is said, “A future physician is a vaccinator”. Hence a pediatrician has to be well informed about the indications and limitations of all the conventional and newer vaccines and should be prepared to respond to the queries of well-informed parents. This book on immunization titled “Immunization in clinical practice” is an authentic source of such information.</p> <p>The book has been divided into four parts: basics, widely used vaccines, immunization in special circumstances and future vaccinology. Various authors from India and abroad have comprehensively and extensively discussed the topics. The extent of the disease burden in our country based on available information is provided in each chapter. Some historical background on each vaccine makes it interesting to read. The common as well as unusual side effects of various vaccines and their management are discussed well. The schedule adopted by Government of India and Indian Academy of Pediatrics (IAP) and the rationale behind the differences if any are described. For the newer vaccines, guidelines based on IAP recommendations are given to the practitioners so that they may make a rational choice. Almost all the chapters are provided with excellent references to stimulate the readers to learn more about immunization. The note worthy features in the book are chapters on safe injection practices, immunization guidelines for all diseases prevalent in our community including rabies and Japanese encephalitis, adolescent and adult immunization and new technologies and future vaccines. The chapter on combination vaccines backed up by good evidence will help the pediatrician in decision-making. ‘Literature on immunization available in internet’ is a good valuable addition. The book is written in simple English and the print and lettering are reader friendly.</p> <p>A few points need clarification. It has been mentioned under ‘Immunization against Diphtheria, Tetanus and Pertussis’ (Chapter 8) that these vaccines may be kept in cool and dark place in case of electrical failure. It should be remembered that cold chain should be maintained between +2°C to +8°C under all circumstances by appropriate method (vaccine carrier, back-up generator etc). Some simple errors like DTP at birth in IAP schedule (Chapter 3) and the ambiguity about one syringe and two needles for each vaccination (Chapter 5 and 6) and passive immunity for pertussis from mother to infant (partial - chapter 3; absent – chapter 8) could have been avoided. Clearcut guidelines could have been provided for BCG vaccination in preterm / low birth weight infants on similar lines as given for hepatitis B vaccine and the need / otherwise for repeat BCG vaccination when there is no scar following immunization. Under the chapter “Immunization against poliomyelitis” a brief note on acute flaccid paralysis (AFP) surveillance would have been useful.</p> <p>As the editors have pointed it out in the preface, the topic of immunization evokes tremendous interest and many queries in the minds of pediatricians. The book through, inspite of its few ambiguities is a comprehensive evidence based review on immunization, which will be of great use to pediatricians, postgraduates and general practitioners and is worth possessing for ready reference for immunization practice.</p> |
| Publishers | M/s. Jaypee Brothers Medical Publishers (P) Ltd., EMCA House, 23/23 B Ansari Road, Daryaganj, New Delhi – 110 002. India. |
| Price | Rs.250/- |

NEWS AND NOTES

XVII Annual Conference of the Indian Pediatric Nephrology Group

The XVII Annual Conference of Indian Pediatric Nephrology Group is being organized on 26th - 27th November 2005 at the Auditorium, St. John's Medical College Hospital, Bangalore.

The faculty will comprise of eminent specialists from different parts of the country. The scientific program is designed to provide valuable and relevant information on various issues in pediatric nephrology faced by practising pediatricians and pediatric nephrologists. There will be award paper session to encourage young trainees to present their original work in the field of pediatric nephrology.

Registration Fee :

| | From 30th Sep. to 31st Oct. 2005 | From Oct. 1 to 15th Nov. 2005 | After 15th Nov. 2005 |
|-----------|-------------------------------------|----------------------------------|----------------------|
| Delegates | Rs. 800 | Rs. 1,200 | Rs. 1,600 |
| PGs | Rs. 500 | Rs. 500 | Rs. 500 |

Payment may be made by draft payable to "IPNGCON 2005" at Bangalore. Kindly add Rs. 50 for outstation cheques.

For further details please contact: **Dr. Arpana Iyengar**, Organising Secretary, XVII Annual Conference of IPNG, Children's Kidney Care Center, Department of Pediatrics, St. John's Medical College Hospital, Bangalore 560 034. Phone (O): 080-22065284. Fax: 080-2553-0070. E-mail: ipng2005@gmail.com

The Dakshin

SOUTH PEDICON 2005

19th South Zone Conference &
34th Annual Conference of IAP Kerala State Branch

on 30th September, 1st & 2nd October, 2005 at Thiruvananthapuram, Kerala

Theme : Healthy Child; A National treasure

Venue : Co-Bank Towers & Mascot Hotel

Pre-conference CME : 30th September, Conference : 1st & 2nd October.

| | Till 15.05.2005 | Till 1.07.2005 | Till 15.09.2005 | After 15th Sep. 2005 & spot |
|----------------|--------------------|-------------------|--------------------|--------------------------------|
| IAP Member | 1200 | 1500 | 2000 | 2500 |
| Non IAP Member | 1500 | 1750 | 2250 | 3000 |
| PG Students | 750 | 1000 | 1250 | 1500 |

Payments by DD in favour of "South Pedicon 2005" payable at Thiruvananthapuram. Outstation cheques to add Rs.50/-

M.K.C. Nair, *Princial Advisor*

Lalitha Kailas, *Org. Chairperson*

Correspondence to : **M.Zulfikar Ahmed**, Organizing Secretary "South Pedicon 2005" Dept. of Pediatrics, SAT Hospital Medical College, P.O. Thiruvananthapuram - 695 011, Phone : 0471-2528437



INDIAN JOURNAL OF PRACTICAL PEDIATRICS

SUBSCRIPTION TARIFF



JOURNAL OFFICE

IAP TNSC Flat, Ground Floor, F Block,

Halls Towers, 56/33 Halls Road, Egmore,

Chennai 600 008.

Phone: +91-44-28190032, 52052900.

Email: ijpp_iap@rediffmail.com

Official Journal of the Indian Academy of Pediatrics

A quarterly medical journal committed to practical

pediatric problems and management update

For office use

Ref. No.

Cash / DD for Rs.

DD No.

Receipt No. & Date

Enter year

Subscription years
for

Name

Address

City State

Pin Phone (R) (O)

Mobile Email

Designation Qualification

I am enclosing a DD No. dated drawn on

favoring **Indian Journal of Practical Pediatrics** for Rs.

Signature

Subscription rate

| | | | |
|-------------|-----------|------------|--|
| Individual | Annual | Rs.300/- | Send your subscription, only by crossed demand draft, drawn in favour of INDIAN JOURNAL OF PRACTICAL PEDIATRICS , payable at Chennai and mail to Dr.A.BALACHANDRAN, Editor-in-Chief, "F" Block, No.177, Plot No.235, 4th Street, Anna Nagar East, Chennai - 600 102, Tamilnadu, India. |
| | Ten Years | Rs.3000/- | |
| Institution | Annual | Rs.400/- | |
| | Ten Years | Rs.4000/- | |
| Foreign | Annual | US \$ 50/- | |

INDIAN JOURNAL OF PRACTICAL PEDIATRICS

ADVERTISEMENT TARIFF

Official Journal of the Indian Academy of Pediatric - A quarterly medical journal committed to practical pediatric problems and management update

| Name | | FULL PAGE | |
|---------------|-----------|--------------|--------------|
| Address | | B/W | Colour* |
| | | Ordinary | 5,000 10,000 |
| | | Back cover | - 15,000 |
| | | Second cover | - 12,000 |
| City | | Third cover | - 12,000 |
| State | Pin | | |

* Positives of the advertisements should be given by the company.

Signature

Kindly send your payment by crossed demand draft only drawn in favour of
“Indian Journal of Practical Pediatrics” and art work / matter to

MANAGING EDITOR

Indian Journal of Practical Pediatrics
IAP-TNSC Flat, Ground Floor,
F Block, Halls Towers,
56 (Old No.33), Halls Road,
Egmore, Chennai - 600 008. India
Phone : 2819 0032
Email : ijpp_iap@rediffmail.com



Indian Journal of Practical Pediatrics

Subscription Journal of the
Indian Academy of Pediatrics



JOURNAL COMMITTEE

Editor-in-Chief

Dr. A. Balachandran

Executive Editor

Dr. K. Nedunchelian

Managing Editor

Dr. Malathi Sathiyasekaran

Associate Editors

Dr. N. C. Gowrishankar

Dr. P. Ramachandran

Dr. C. V. Ravisekar

Dr. V. Sripathi

Dr. S. Thangavelu

Executive Members

Dr. G. Durai Arasan

Dr. Janani Sankar

Dr. S. Lakshmi

Dr. V. Lakshmi

Dr. (Major) K. Nagaraju

Dr. T. Ravikumar

Dr. S. Shanthi

Dr. So. Shivbalan

Dr. C. Vijayabhaskar

Dr. Bharat R. Agarwal
(Ex-officio)

NATIONAL ADVISORY BOARD

President, IAP

Dr. Raju C. Shah

President 2006, IAP

Dr. Nitin K. Shah

Editor, Indian Pediatrics

Dr. Panna Choudhury

Members

Col. M. K. Behera

Dr. M. Govindaraj

Dr. B. D. Gupta

Dr. C. B. Dass Gupta

Dr. Dinesh Khosla

Dr. Nigam Prakash Narain

Dr. Rohit Agarwal

Dr. V. N. Tripathi

Dr. Yashwant Patil

Emeritus Editors

Dr. A. Parthasarathy

Dr. B. R. Nammalwar

Dr. M. Vijayakumar



IAP Team - 2005

President

Dr.Raju C Shah

President-2006

Dr.Nitin K Shah

President-2004

Dr..M.K.C.Nair

Vice President

Dr.Anoop Kumar Verma

Secretary General

Dr.Bharat R. Agarwal

Treasurer

Dr.Deepak Ugra

Editor-in-Chief, IP

Dr.Panna Choudhury

Editor-in-Chief, IJPP

Dr.A.Balachandran

Joint Secretary

Dr.A.K.Dutta

Members of the Executive Board

Andhra Pradesh

Dr.V.Ram Narsimha Reddy

Dr.P.Venkateshwara Rao

Assam

Dr.Garima Saikia

Bihar

Dr.Radha Krishna Sinha

Chandigarh

Dr.R.K.Marwaha

Delhi

Dr.Ajay Gambhir

Dr.Anupam Sachdeva

Gujarat

Dr.Baldev S Prajapati

Dr.Satish V Pandya

Haryana

Dr.Dinesh Khosla

Jharkhand

Dr.Brij Bhushan Sahni

Indian Academy of Pediatrics

Kailash Darshan,
Kennedy Bridge,
Mumbai - 400 007.

Karnataka

Dr.M.Govindaraj

Dr.Santosh T Soans

Kerala

Dr.T.M.Ananda Kesavan

Dr.M.A.Mathew

Dr.T.U.Sukumaran

Madhya Pradesh

Dr.M.L.Agnihotri

Dr.Chandra Has Sharma

Maharashtra

Dr.Pramod Jog

Dr.Rajendra V Kulkarni

Dr.Sandeep Babu Kadam

Dr.Yashwant Patil

Manipur

Dr.K.S.H.Chourjit Singh

Orissa

Dr.Gadadhar Sarangi

Punjab

Dr.Harmesh Singh

Rajasthan

Dr.B.D.Gupta

Tamilnadu

Dr.D.Gunasingh

Dr.K.Meer Mustafa Hussain

Dr.P.Velusamy

Uttar Pradesh

Dr.Ashok Kumar Rai

Dr.V.N.Tripathi

Dr.Vineet K Saxena

West Bengal

Dr.Debasis Biswas

Dr.Sukanta Chatterjee

Services

Col.M.K.Behera

President's Spl. Representative

Dr.Rajesh Mehta

A.A.A.

Dr.Tanmay Amladi